

Materials needed

- Computer with DVD capability
- LCD projector
- "Curve Checks" DVD
- Pretest forms—one per participant (see appendix)
- Evaluation forms—one per participant (see appendix)
- Curve Checks Reference Guide—one per participant (copy if needed to provide one for each professional)
- Screening form—one per participant (see appendix)
- "Curve Checks" DVD quiz sheet—one per participant (see appendix)
- "Curve Checks" DVD quiz answer key—one per participant (see appendix)
- Practicum form (see appendix)
- Scenarios form (see appendix)

How to use this section

- Scoliosis Screening for Healthcare Professionals is a PowerPoint presentation designed for the instructor's use.
 - The PowerPoint presentation within the manual provides note pages to guide the instructor regarding information on each slide. Note pages contain instructions for the instructor and suggested verbal information to share with other healthcare professionals.
- Download to prepare for training:
 - Powerpoint presentation from choa.org/scoliosis
 - "Curve Checks" DVD
- Handouts can also be printed from the PowerPoint rather than using the Curve Checks Reference Guide.
 - Go to *Adobe/File/Print*. Under Page Sizing & Handling section choose Multiple pages per sheet. Adjust Pages per sheet to number of slides desired.
- As an instructor, preview the DVD with note pages to determine the chapters that are applicable to your healthcare professionals and timeframe.

Scoliosis screening for healthcare professionals



Slide 1

- Prior to class, download the Scoliosis Screening for Healthcare Professionals PowerPoint presentation.
- As healthcare professionals enter the room, pass out the following materials:
 - Pretest–healthcare professionals can take the test prior to beginning the presentation
 - Curve Checks Reference Guide–ask them to review Page 1
 - Screening form
 - DVD quiz sheet
 - DVD quiz answer key (if reference guide not available)
 - Practicum form
 - Scenarios form

Introductions

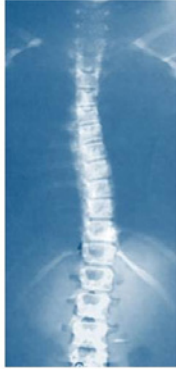

Slide 2

- Introduce yourself and anyone else teaching the class.
- Tell participants something about yourself as it relates to your role and experience with scoliosis screening.
 - How long have you been screening children for scoliosis?
 - Explain your special interest in scoliosis screening.

Overview of scoliosis

- Description and definition



Children's Healthcare of Atlanta



3

Slide 3

Description: Scoliosis is a lateral or sideways deviation or curve from the normal vertical line sagittal plane of the spine, which when measured by X-ray is greater than 10 degrees. This X-ray shows a curve of 9 degrees.

Overview of scoliosis

Myths ☹️

1. Back pain is an indicator for idiopathic scoliosis.
2. Backpacks cause scoliosis.
3. Bad bedding can cause scoliosis.
4. Bad posture causes scoliosis.

Facts 😊

1. Adolescent Idiopathic Scoliosis has few symptoms.
2. 30 percent of families have a history of scoliosis.
3. Scoliosis affects 2 to 3 percent of the adolescent population.
4. Vertebrae changes are multifactorial.

Children's Healthcare of Atlanta



4

Slide 4

Myth 1. Back pain is an indicator for idiopathic scoliosis.

Fact: AIS has few physical symptoms. Back pain is not usually associated with AIS, but pain may be caused by other conditions.

Myth 2. Backpacks cause scoliosis.

Fact: Scoliosis runs in families.

Myth 3. Bad bedding can cause scoliosis.

Fact: Scoliosis affects 2 to 3 percent of the adolescent population.

Myth 4. Bad posture causes scoliosis.

Fact: Vertebrae shape change is due to interrelated physical responses not yet fully understood.

Overview of scoliosis

- Statistics
- Consequences of untreated scoliosis
- Treatments
 - Observation
 - Orthopaedic intervention
 - Orthotics (spinal brace)
 - Surgery

Slide 5

Statistics:

- 2 to 3 percent of the population has scoliosis
- 0.5 percent need orthopaedic intervention

Consequences of untreated scoliosis:

- Back pain
- Cosmetic concerns regarding the way clothing hangs on the body
- Surgical complexity due to positioning and decreased lung function
- High treatment costs related to surgery and postoperative management

Treatments:

- Observation or recheck by physician of adolescents with curves until they reach adult height or skeletal maturity
- Orthopaedic intervention, including bracing (orthotics)
 - A spinal brace is prescribed when the curve reaches about 20 to 25 degrees. It is worn under clothes or at night during the adolescent growth period.
 - The goal of orthotics is to prevent the curve from progressing and to avoid surgical correction.
 - Surgery may be needed if the curve progresses beyond 47 degrees.

Orthopaedic management related to X-rays

- Curve Checks Reference Guide, Page 3
 - 9 degrees
 - 15 degrees
 - 26 degrees
 - 30/30 degrees
 - 52/30 degrees
 - 85 degrees

Slide 6

Let's review some X-rays to relate degrees of curve to orthopaedic management:

Turn to Page 3 in the Curve Checks Reference Guide.

- 9-degree curve: Spinal asymmetry. The body can tolerate this small degree of curve without consequences.
- 15-degree curve: Orthopaedic observation begins. Periodic rechecks are required by the orthopaedic specialist.
- 26-degree curve: Orthopaedic intervention begins. This may include orthotics or brace treatment. The goal of intervention is to keep the curve from progressing.
- 30-degree double curve: Curves of 30 degrees or more are at risk for progression even after skeletal maturity. These curves will need orthopaedic intervention during adolescence with periodic observation throughout adulthood.
- 52-degree thoracic curve with compensatory 30-degree curve: Surgical correction is indicated. This curve will probably progress over the adult lifetime if not surgically corrected.
- 85-degree thoracic curve: Results in decreased pulmonary function and patients experience shortness of breath. Can you see the difference in the rib cage when you look at the right and left side of the ribs?
- Adults with curves of 30 degrees or more may experience back pain, osteoarthritis of the spine and potential significant deformity if curve increases.

Overview of scoliosis

- Types of scoliosis
 - Congenital
 - Neuromuscular
 - Idiopathic
 - Mechanical
 - Other

Children's Healthcare of Atlanta



7

Slide 7

Types

- Congenital–Bony abnormalities of the spine present at birth.
- Neuromuscular–Scoliosis is a secondary diagnosis due to a condition related to the central nervous system, such as cerebral palsy, muscular dystrophy or spina bifida.
- Idiopathic–The cause has not yet been determined.
- Mechanical–Associated with a condition that may initially manifest as scoliosis, however, underlying cause is another condition such as leg-length discrepancy.
- Other–Associated with bone tumors or infections that present as a curvature with pain.

Conditions associated with scoliosis

- Neurofibromatosis
- Down's syndrome
- History of thoracotomy for esophageal atresia, cardiac and pulmonary disorders
- Prader-Willi syndrome
- Noonan syndrome
- Osteogenesis imperfecta
- Pectus excavatum and pectus carinatum
- Klippel-Feil syndrome
- Sprengel's deformity
- Chiara malformation
- Marfan's syndrome

Children's Healthcare of Atlanta



8

Slide 8

Here is a list of conditions that are associated with scoliosis. As healthcare professionals, it is important to be aware of these associated conditions.

- Neurofibromatosis
- Down's syndrome
- History of thoracotomy for esophageal atresia, cardiac and pulmonary disorders
- Prader-Willi syndrome
- Noonan syndrome
- Osteogenesis imperfecta
- Pectus excavatum and Pectus carinatum
- Klippel-Feil syndrome
- Sprengel's deformity
- Chiara malformation
- Marfan's syndrome

"Curve Checks" DVD

- What is scoliosis?
- What causes scoliosis?
- Why is screening important?
- How is scoliosis treated?
- What is my role as a screener?
- Screening preparation

Children's Healthcare of Atlanta



9

Slide 9

Explain to healthcare professionals: "Curve Checks" DVD is designed to give you background information about scoliosis and teach you how to screen. You can follow along in your Curve Checks Reference Guide or watch the video.

- Play the "Curve Checks" DVD—Chapter 1 (Introduction) to Chapter 7 (Screening Preparation).
- Pause DVD.

Observe a screening

- Chapter 8, Normal Screening, Daniella

Slide 10

Hand out the screening form or have participants pull the screening form from their packet. Explain to healthcare professionals that we are ready to review a normal screening.

- Play Chapter 8 (Daniella).

After DVD plays, the instructor may pause the video if there is time and discuss kyphosis as noted in Daniella's screening.

- Daniella is normal until she turns to side and the C curve is not within normal limits.
- She has a sharp angulation or abnormal contour, which is not easily seen in the video.
- Note that in the anterior view, the child's right is on the opposite side as you look at the child. In the posterior view, the right of the child is on your right.

Inform the participants whether the children to be screened have seen the "Scoli What?" video on choa.org/scoliosis as an introduction to scoliosis and what is expected of them during the screening.

- "Scoli What?" is a six-minute video for adolescents to give them information about scoliosis and to show them how to stand and bend during the screening.
- If "Scoli What?" has not been shown, inform the participants that the students may need additional instruction and coaching through the screening process.

5 steps to scoliosis screening

- Receive the screening form from the child
 - Review form
 - Check that demographic information is complete
 - Or
 - Preprinted label is attached

Slide 11

The child will give you the screening form. The demographic portion will be completed. Check the form to see that the demographic section is fully completed.

As you screen the child, you will check any abnormalities you note. You will sign the form and indicate your status: healthcare professional, school nurse, etc.

5 steps to scoliosis screening

- Greet the child by name
 - Shoes off for screening
- Ask the child to
 - Step up to the line.
 - Put your feet together, weight equally on both legs.
 - Take a breath in. Let it out and let your arms hang naturally at your sides.

Slide 12

Greet the child by name.

- Instruct child to remove shoes for the screening.

Instruct the child to:

- Step up to the line.
- Put your feet together, weight equally on both legs.
- Take a breath in. Breathe out and let your arms hang naturally at your sides.


Check to make sure the child is standing correctly. The inner ankle bones (medial malleolus) should be touching. If the child cannot put his feet together, he can stand with his feet slightly apart. Make sure the inner malleoli at the ankle or hindfoot are aligned.

5 steps to scoliosis screening

- Step 1: Anterior view

- Observe for truncal asymmetry:

- Shoulder height asymmetry at lateral end of clavicle
- Unequal distance between arms and torso—one arm hangs out from torso more than the other
- Uneven pelvis—one hip appears higher/more prominent than the other



Children's Healthcare of Atlanta  13

Slide 13

Observe the lateral ends (outside ends) of the clavicle.

Check for shoulder height asymmetry. On the screening form, check the higher shoulder.

Check for unequal distance between the arms and torso. Check and note the arm that hangs out further from the body.

Does the pelvis appear uneven? On the screening form check the side of the pelvis that appears higher. To visualize pelvic asymmetry you may ask the child to put his hands on the top of his hips.

5 steps to scoliosis screening

- Step 2: Adams Forward Bend Test

Instruct child:

- Put the palms of your hands together, arms out straight.
- Put your chin on your chest. Roll down until hands touch your feet.



Children's Healthcare of Atlanta  14

Slide 14

Instruct the child to:

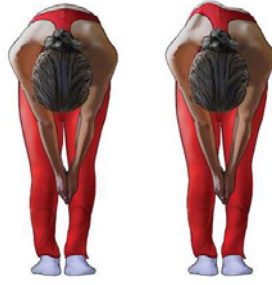- Put the palms of your hands together, arms out straight.
- Put your chin on your chest.
- Keep your knees straight and roll down until your hands touch your feet.

The student's back should be parallel to the floor.

5 steps to scoliosis screening

- Step 2: Continued

- Observe for torso asymmetry
 - Upper thoracic prominence
 - Lower thoracic prominence
 - Lumbar prominence



Children's Healthcare of Atlanta  15

Slide 15

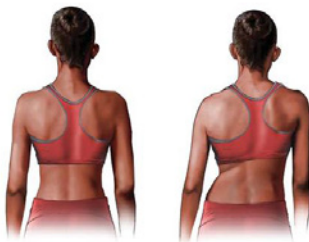Look for:

- High thoracic prominence
- Low thoracic prominence
- Lumbar prominence

Mark screening form if prominence is noted and which side is higher.

5 steps to scoliosis screening

- **Step 3: Posterior view**
- Instruct Child: Turn around and put your toes on the line, weight equally on both legs. Take a breath in. Let it out, and let your arms hang at your sides.
- **Observe for truncal asymmetry:**
 - Asymmetry of shoulders
 - Scapula prominence and/or asymmetry
 - Waist crease asymmetry
 - Unequal distance of arms to torso
 - Spinal curvature



Children's Healthcare of Atlanta  16

Slide 16

Ask the child to turn around.

Give the following instructions:

- Put your feet together, weight equally on both legs.
- Take a breath in.
- Breathe out, and let your arms hang at your sides.

Recheck to make sure the child is standing correctly—the inner malleoli or hindfoot are aligned.

Check for shoulder height asymmetry. On the screening form, check the higher shoulder.

Check for scapular prominence or asymmetry. On the screening form, check the higher or more prominent scapula.

Check for waist-crease asymmetry or no waist crease on one side. On the screening form, note the side of the deeper waist crease.

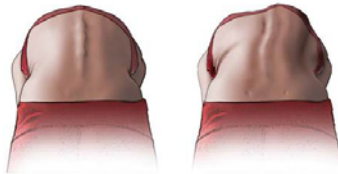
Check to see if one arm hangs out farther from the torso. On the screening form, note the arm that hangs out further from the torso.

Check for a visible spinal curvature.

Check for a truncal shift—C7T1 aligns with gluteal cleft.

5 steps to scoliosis screening

- **Step 4: Bending away**
- Instruct child: Put the palms of your hands together, arms out straight. Put your chin on your chest. Roll down until your hands touch your feet.
- **Observe for truncal asymmetry:**
 - Upper thoracic prominence
 - Lower thoracic prominence
 - Lumbar prominence



Children's Healthcare of Atlanta  17

Slide 17

Instruct the child to:

- Put the palms of your hands together, arms out straight.
- Put your chin on your chest.
- Roll down until your hands touch your feet.

The student's back should be parallel to the floor.

Look for:

- High thoracic prominence
- Low thoracic prominence
- Lumbar prominence

Mark the screening form if prominence is noted and which side is higher.

5 steps to scoliosis screening

- Step 5: Sagittal view
- Instruct child: Turn to the side and put your feet together. Put the palms of your hands together, arms out straight. Put your chin on your chest. Roll down until hands touch your feet.
- Look for sharp angle—
abnormal contour in lower
thoracic area (kyphosis)



Children's Healthcare of Atlanta  18

Slide 18

Instruct the child to:

- Turn to your side, feet together.
- Put the palms of your hands together, arms out straight.
- Put your chin on your chest.
- Roll down until your hands touch your feet.

The student's back should be parallel to the floor.

Observe for sharp angulation and abnormal contour (kyphosis). Note sharp angulation on the screening form.

Thank the child for coming.

Questions

Children's Healthcare of Atlanta  19

Slide 19

Ask participants if they have any questions regarding the five-step process.

“Curve Checks” DVD

- Chapters 9 through 14, Screening Children
 - Karlena
 - Erin
 - Brittany
 - Christopher
 - Alexis
 - Valentina
- “Curve Checks” DVD quiz

Slide 20

Pass out "Curve Checks" DVD quizzes to participants.

Explain to healthcare professionals: Here is an opportunity to practice. Let's watch the DVD and circle positive findings on the quiz sheet. The DVD is a 2-D presentation. In real life, the screening is 3-D, therefore makes it easier to visualize differences.

Return to DVD: Play Chapter 9 (Karlena) through Chapter 14 (Valentina), or play each chapter one at a time and then discuss.

Karlena: Classic signs of thoracic scoliosis—right shoulder elevation, right scapula elevation, right thoracic prominence.

Erin: Negative exam or no signs of scoliosis until viewing lower back or lumbar area. This is why it is important to carefully check the lumbar area.

Brittany: Possible hip height difference, or pelvic asymmetry. Thoracic prominence in posterior view but not in the anterior. Refer child. She also has lumbar prominence.

Christopher: Notice the importance of rolling the scapula off the ribs in the back to get a good view.

Alexis: It is important to make sure she positions her feet properly; she appears nervous. She also needs to be encouraged to roll down further to see her lumbar area. Although the screening is inconsistent with regards to arm and torso distance in the anterior view and the posterior view, she has additional positive signs that indicate she should be referred. If there is time, the screener can repeat the positioning in the anterior and posterior views.

Valentina: Due to the 2-D DVD presentation, it is hard to visualize the findings. In a real screening, this will be easier to see.

Questions

Slide 21

Pass out quiz answer key, or have participants turn to Page 9 in Curve Checks Reference Guide.

- Ask screeners if they have questions.
- Screeners will note recommendation as negative or referral for positive screening results.

"Curve Checks" DVD

- Chapter 15, Your Job is Important

Slide 22

Play Chapter 15 of "Curve Checks" DVD.

Documentation—screener

- Mark abnormal findings on screening form.
 - Anterior view
 - Posterior view
 - Sagittal view
 - Check negative or positive
 - Print name
 - Check category of screener's credentials
 - Record any concerns

Slide 23

Once the screening is complete, check whether it was negative (no abnormal findings) or positive.

- Print your name.
- Check the category of screener based on your credentials.
- Under screener notes, record any concerns—a mole, large abrasion, pustule, burn or large bruise.
- Let the school authority at the screening know if you have concerns.

Discuss the process for how screeners should report concerns on the day of the screening.

Demonstration and/or practice

- Demonstration of practicum
- Practicum
- Screening scenarios

Slide 24

Demonstrate how to use the practicum form.

- As the instructor, you can review a screening using volunteers from the present healthcare professionals as a screener and coach.

Practicum

- You may also have healthcare professionals practice on each other.
 - Divide into small groups of three—screener, screenee and coach.
 - Use practicum form from the appendix.
- Walk around the room to see if participants have questions regarding the screening steps.

Scenarios

- Have participants fill out screening scenarios form.
 - Review each screening scenario.

Screening scenarios

Screening No. 1—Katie

- *In front position:*
 - Shoulders are even
 - Arm hangs out from body more on left
 - Hips appear even
- *As she bends forward:*
 - No rib prominence
 - No lumbar prominence
- *In back position:*
 - Shoulders are even
 - Scapulae are even
 - Waist fold is slightly deeper on left
 - Left arm hangs out from her body
- *As she bends forward:*
 - Slight rib prominence on right
 - No lumbar prominence
- *In side view:* C-shaped curve
- **Is she a positive screen?** **Yes** **No**



Slide 25

Katie is a positive screen for scoliosis.

She needs to be referred for a positive screening.

Screening scenarios

Screening No. 4—Katie

- **In front position:**
 - Shoulders are even
 - Arm hangs out from body more on left
 - Hips appear even
- **As she bends forward:**
 - No rib prominence
 - No lumbar prominence
- **In back position:**
 - Shoulders are even
 - Scapulae are even
 - Waist fold is slightly deeper on left
 - Left arm hangs out from her body
- **As she bends forward:**
 - Slight rib prominence on right
 - No lumbar prominence
- **In side view:**
 - C-shaped curve
- **Is she a referral?** Yes No
- **Why or why not?** _____

Children's Healthcare of Atlanta



26

Slide 26

Reviewing her screening, the positive signs of scoliosis are:

– Anterior position:

Her arm hangs farther out from her body on left.

– Posterior position:

Her waist folds slightly deeper on the left.

Her arm hangs farther out from her body on the left.

There is a slight rib prominence on right.

Yes, she is a referral for a positive screening.

Why:

She has positive signs, including a rib prominence noted in the posterior position.

A rib or lumbar prominence may only be seen in either the anterior or posterior position. It may be easier to see in one position over the other. It does not need to be seen in both positions to be considered a positive screening and referral.

Screening is not a diagnosis. Screening notes signs that need further investigation.

If you have time, you can ask the child to repeat the positioning of the feet and the Adams Forward Bend Test in both positions.

Screening scenarios

Screening No. 2—Alonzo

- **In front position:**
 - Shoulders are even
 - Arms hang evenly from body
 - Right hip appear higher than left
 - With hands on hips — right hip appears higher
- **As he bends forward:**
 - Right lumbar prominence
- **In back position:**
 - Difficulty maintaining correct feet position
 - Shoulders are even
 - Scapulae are even
 - Waist folds are even
 - Arms hang evenly at his sides
- **As he bends forward:**
 - No prominence
- **In side view:**
 - C-shaped curve
- **Is he a positive screen? ___ Yes ___ No**

Children's Healthcare of Atlanta



27

Slide 27

Alonzo is a positive screening for hip height difference and lumbar prominence in the anterior position.

Screening scenarios

Screening No. 2—Alonzo

- **In front position:**
 - Shoulders are even
 - Arms hang evenly from body
 - Right hip appear higher than Left
 - With hands on hips – right hip appears higher
- **As he bends forward:**
 - Right lumbar prominence
- **In back position:**
 - Difficulty maintaining correct feet position
 - Shoulders are even
 - Scapulae are even
 - Waist folds are even
 - Arms hang evenly at his sides
- **As he bends forward:**
 - No prominence
- **In side view:**
 - C-shaped curve
- **Is he a referral? Yes No**
- **Why or why not? _____**

Children's Healthcare of Atlanta



28

Slide 28

Yes, he is a positive referral notification.

Why:

Hip height difference can cause a lumbar prominence. This is the category of mechanical scoliosis.

He needs a referral because the hip height difference may need treatment. The younger he is, and therefore the less mature his skeleton, the more he is at risk for developing increased hip height difference or increased leg length difference. When the skeleton is immature, there is a window of time when hip height difference can be treated, or he might have lumbar scoliosis and the hip height difference may be minimal.

He needs to be seen by a pediatric orthopaedic physician for an evaluation of these findings.

Screening scenarios

Screening No. 2—Samantha

- **In front position:**
 - Right shoulder higher than left
 - Arms hang evenly from body
 - Hips appear even
- **As she bends forward:**
 - Right rib prominence
 - Lumbar area is even
- **In back position:**
 - Shoulders are even
 - Right scapula is elevated & more pronounced
 - Waist folds are even
 - Arms hang evenly from body
- **As she bends forward:**
 - Right rib prominence
 - No lumbar prominence
- **In side view:**
 - C-shaped curve
- **Is she a positive screen? ___Yes___ No**

Slide 29

Samantha is a positive screen for scoliosis.

She has a rib prominence on the right in both the anterior and posterior positions.

Screening scenarios

Screening No. 2—Samantha

- **In front position:**
 - **Right shoulder higher than left**
 - Arms hang evenly from body
 - Hips appear even
- **As she bends forward:**
 - **Right rib prominence**
 - Lumbar area is even
- **In back position:**
 - Shoulders are even
 - **Right scapula is elevated and more pronounced**
 - Waist folds are even
 - Arms hang evenly from body
- **As she bends forward:**
 - **Right rib prominence**
 - No lumbar prominence
- **In side view:**
 - C-shaped curve
- **Is she a referral?** **Yes** **No**
- **Why or why not?** _____

Children's Healthcare of Atlanta



30

Slide 30

Yes, she is a positive screening notification.

Why:

Although in the anterior position, her shoulders are uneven and in the posterior position her shoulders are even, she has a rib prominence in both positions, and scapula asymmetry in the posterior position.

Screening scenarios

Screening No. 4—Nikolas

- *In front position:*
 - Shoulders are even
 - Arms hang evenly from body
 - Hips appear even
- *As he bends forward:*
 - Left rib elevation
 - Left lumbar elevation
- *In back position:*
 - Left shoulder elevation
 - Left scapulae elevation
 - Waist folds are even
 - Arms hang evenly at his sides
- *As he bends forward:*
 - Left rib elevation
 - Then a right rib elevation
 - Then a left lumbar elevation
- *In side view:*
 - C-shaped curve
- **Is he a positive screen? Yes No**



Slide 31

Nikolas is a positive screen for scoliosis.

Screening scenarios

Screening No. 4—Nikolas

- *In front position:*
 - Shoulders are even
 - Arms hang evenly from body
 - Hips appear even
- *As he bends forward:*
 - Left thoracic elevation
 - Left lumbar elevation
- *In back position:*
 - Left shoulder elevation
 - Left scapulae elevation
 - Waist folds are even
 - Arms hang evenly at his sides
- *As he bends forward:*
 - Left thoracic elevation
 - Then a right thoracic elevation
 - Then a left lumbar elevation
- *In side view:*
 - C-shaped curve
- *Is he a referral?* Yes No
- *Why or why not?* _____

Children's Healthcare of Atlanta



32

Slide 32

Yes, Nikolas needs a referral.

Why:

He may very well have three curves, an atypical curvature pattern. This can be more difficult to treat.

Screening scenarios

Screening No. 5—Madison

- *In front position:*
 - Shoulders are even
 - Arms hang evenly from body
 - Hips appear even
- *As she bends forward:*
 - No rib prominence
 - No lumbar prominence
- *In back position:*
 - Shoulders are even
 - Scapulae are even
 - Waist folds are even
 - Arms hang evenly from body
- *As she bends forward:*
 - No rib elevation
 - No lumbar prominence
- *In side view:*
 - C-shaped curve
- **Is she a positive screen? ___ Yes ___ No**

Slide 33

Madison is a negative screen for scoliosis.

Screening scenarios

Screening No. 5—Madison

- *In front position:*
 - Shoulders are even
 - Arms hang evenly from body
 - Hips appear even
- *As she bends forward:*
 - No rib prominence
 - No lumbar prominence
- *In back position:*
 - Shoulders are even
 - Scapulae are even
 - Waist folds are even
 - Arms hang evenly from body
- *As she bends forward:*
 - No rib elevation
 - No lumbar prominence
- *In side view:*
 - C-shaped curve
- *Is she a referral?* Yes No
- *Why or why not?* _____

Children's Healthcare of Atlanta  34

Slide 34

No, she does not need a referral.

Notes:

The examples today have been more positive screenings for instructional purposes.

We have discussed more positives than negatives today.

In the real world of screening, it will be the other way around, more negatives than positives.

When screening there should be about a 5 percent positive referral rate (range of 4 to 6 percent).

Screening scenarios

Screening No. 6—Jacob

- *In front position:*
 - Shoulders are even
 - Arms hang evenly from body
 - Hips appear even
- *As he bends forward:*
 - No rib prominence
 - No lumbar prominence
- *In back position:*
 - Shoulders are even
 - Arms hang evenly from body
 - Waist folds are even
 - Arms hang evenly at his sides
- *As he bends forward:*
 - No rib prominence,
 - No lumbar prominence
- *In side view:*
 - Hump in the middle of his back
- **Is he a positive screen? ___Yes___No**

Slide 35

Jacob is a positive screen for sagittal plane deformity.

He has a prominence, rather than a C-shaped curve.

In the sagittal plane, you may also notice that the tragus, the flap of cartilage in front of the ear is anterior to the shoulder.

Screening scenarios

Screening No. 6—Jacob

- *In front position:*
 - Shoulders are even
 - Arms hang evenly from body
 - Hips appear even
- *As he bends forward:*
 - No rib prominence
 - No lumbar prominence
- *In back position:*
 - Shoulders are even
 - Arms hang evenly from body
 - Waist folds are even
 - Arms hang evenly at his sides
- *As he bends forward:*
 - No rib prominence
 - No lumbar prominence
- *In side view:*
 - Prominence in the middle of his back
- *Is he a referral?* Yes No
- *Why or why not?* _____

Children's Healthcare of Atlanta



36

Slide 36

Yes, he needs a referral.

Why:

This is known as Scheuermann's kyphosis.

The prevalence of kyphosis is 2.8 percent, a little less than three percent in the population.

The male to female ratio is 2:1, so it is seen twice as often in males when compared to females. It can cause deformity and pain.

Additional screenings—"Curve Checks" DVD

- Jasmine
- Mahogany

Slide 37

See screening scenarios form.

Review the findings:

- Jasmine needs to be encouraged to roll down. She has more subtle signs that are not as easy to note on the 2-D DVD.
- Mahogany also needs to be encouraged to roll down because you can miss her lumbar prominence. You might need to ask her to repeat the roll down (Adams forward bend test).

Ask participants if they have any questions.

Screenings in our school

- Accommodations related to our school
- Dates of screening

Slide 38

School accommodations

Tell participants of any accommodations they should be aware of regarding your school such as:

- Where the children will be screened
- Where the children will put their shirts while being screened
- Dates of screenings

Thank you

- Thank you for coming and learning how to screen adolescents for scoliosis.

Slide 39

Thank your participants.

- If you are beginning the screenings, have screeners move to screening area.
- If you are performing the screenings at a later date, give the dates and time of the screenings.