

Scoliosis Screening Manual

Training Program for
Healthcare Professionals



Children'sSM
Healthcare of Atlanta

Table of contents

Introduction

Welcome.....	3
Goal.....	4
Objectives for instructors.....	4
Objectives for screeners	4

Legislative authority

Overview.....	5
Georgia General Assembly Code.....	5
Georgia Legal Rules Promulgated from the Scoliosis Code.....	6

Screening overview

Description	8
Establishment of a scoliosis screening program	8
Notification of parents	9
Notification of students.....	9
Preparation	9
Designated screening area.....	10
Day of screening	10
Recording	10
Rescreening.....	10
Follow-up activities.....	11

Instruction for healthcare professionals

PowerPoint presentation: Scoliosis Screening for Healthcare Professionals	12
--	----

Instruction for health workers and volunteers

PowerPoint presentation: Scoliosis Screening Instruction for Health Workers and Volunteers.....	44
--	----

Resources

Websites.....	76
Financial assistance and state health plans in Georgia	76
Individualized Healthcare Plan (IHP) for school nurses regarding scoliosis	81

Appendix

Forms	
Pretest form.....	94
Pretest answer key	95
"Curve Checks" DVD quiz	96
"Curve Checks" DVD answer key	97
Scoliosis Screening Instruction Evaluation	98

Scoliosis Screening Practicum Form	99
Screening Scenarios Form	100
Middle school parent newsletter information.....	103
Notification of screening: Letter to parents (English).....	104
Notification of screening: Letter to parents (Spanish).....	105
Fast Facts About Scoliosis for parents (English)	106
Fast Facts About Scoliosis for parents (Spanish)	107
Individual Scoliosis Screening Form	108
School Screening Log	109
Parent Notification of Positive Screening/Referral Form (English).....	110
Parent Notification of Positive Screening/Referral Form (Spanish).....	111
Adolescent idiopathic scoliosis fact sheet	
Backpack information for parents and students (English)	
Backpack information for parents and students (Spanish).....	
Five-step scoliosis screening process for volunteers	
Five-step scoliosis screening process for healthcare professionals.....	

Welcome

The Children's Healthcare of Atlanta Scoliosis Screening Program is dedicated to the education of healthcare professionals, Georgia's children and their families. The program provides a variety of services to the community that includes education about scoliosis for parents, adolescents and healthcare professionals. The program also conducts specialized clinics and annual instruction for screening personnel, including health department nurses, school nurses, volunteers, physical education teachers, school health workers, and primary care physicians and their office personnel.

The specialized clinics, offered at several locations in metro Atlanta, provide further evaluation and follow-up for children with signs of scoliosis who have been referred through school screenings or physicians.

The Scoliosis Screening for Healthcare Professionals and Scoliosis Screening Instruction for Health Workers and Volunteers PowerPoint presentations are resources to aid you in implementing scoliosis screening in your community. The manual is designed to equip screening program coordinators and presenters with instructional tools for training screeners to properly identify signs of scoliosis. It also provides information regarding compliance with state recommendations, requirements, regulations and laws. Visit choa.org/scoliosis for more information and online resources. Call 404-785-7553 to inquire about consultation.

Thank you for your commitment to the health and well-being of Georgia's children.

Goal:

To provide a scoliosis screening resource guide for healthcare professionals working with local public health departments, schools, primary care physicians and other healthcare professionals.

Objectives for instructors:

Know the code, laws, rules and regulations that mandate scoliosis screening in your state.

Design effective scoliosis screening strategies using the components in the Children's Scoliosis Screening for Healthcare Professionals and Scoliosis Screening Instruction for Health Workers and Volunteers PowerPoint presentations.

Utilize the "Scoli What?" video on choa.org/scoliosis to educate students.

Utilize the PowerPoint presentation, PowerPoint note pages and "Curve Checks" DVD to educate screeners.

Objectives for screeners:

Distinguish between myths and facts regarding scoliosis.

Discuss the importance of scoliosis screening for adolescents.

Describe the scoliosis screening process including all five steps.

Report the abnormal physical findings of the scoliosis screening.

Describe the treatment options for scoliosis.

Many states require school scoliosis screening programs authorized by specific state laws and regulations. The specific mandates, policies and guidelines are usually available through the departments of health or education, or online.

The Georgia code and legal rules are provided as an example of such laws and regulations.

Georgia General Assembly Code

20-2-772.

(a) In addition to any other requirements of this part, the Department of Public Health is authorized and directed, in cooperation with the State Board of Education, to promulgate rules and regulations to provide for the screening of public school children for scoliosis.

(b) The rules and regulations promulgated pursuant to subsection (a) of this code section shall not require the prior approval of parents or legal guardians of public school children for the screening of such school children for scoliosis. However, such rules and regulations shall provide for advance written notice of the time of such screening to be given to parents and legal guardians of such public school children. If the parent or legal guardian of a child objects to such child being screened for scoliosis, such child shall be exempt from such screening.

Visit legis.ga.gov to view the Georgia General Assembly Code.

Approved April 5, 1983

Legal Rules Promulgated From the Scoliosis Code

511-5-8-.01 Definitions

Unless a different meaning is required by the context, the following terms as used in these Rules shall have the meaning hereinafter respectively ascribed to them:

- (a) "At Risk Population" means those children who are in the age group 10 through 15 years.
- (b) "Department" means the Georgia Department of Public Health.
- (c) "Health Authority" means the county boards of health or their authorized representatives.
- (d) "School Authority" means the county and municipal boards of education or their authorized representatives.
- (e) "Scoliosis" means a lateral curvature of the spinal column from the mid line that may or may not include rotation or deformity of the vertebrae.
- (f) "Screening Examination" means to pass through a standardized inspection or test approved by the Department.

Authority: O.C.G.A. Secs. 31-2A-6, 20-2-772. History: Original Rule entitled "Definitions" adopted. F. Oct. 15, 2013; eff. Nov. 4, 2013.

511-5-8-.02 Provision for Screening

- (1) The health authority in cooperation with the school authority shall provide screening of public school children in the at risk population.
- (2) Screening shall be offered annually for a minimum of two grades occupied by the at risk population, recognizing that with their earlier maturation females should be screened in early adolescence.
- (3) All children in the at risk population grades selected shall be screened except those children whose parents or legal guardians object in writing to such screening.

Authority: O.C.G.A. Secs. 31-2A-6, 20-2-772. History: Original Rule entitled "Provision for Screening" adopted. F. Oct. 15, 2013; eff. Nov. 4, 2013.

511-5-8-.03 Written Notice

- (1) Parents or legal guardians shall receive written notification from the school authority two weeks prior to the dates on which screening is to occur during the school term.
- (2) If parents or legal guardians object to the screening, they must notify the school authority in writing within five (5) days of having received the screening notification.
- (3) The school authority shall maintain a list of the children's names for whom parents or guardians have filed a written objection and shall make such names known to the health authority.

Authority: O.C.G.A. Secs. 31-2A-6, 20-2-772. History: Original Rule entitled "Written Notice" adopted. F. Oct. 15, 2013; eff. Nov. 4, 2013.

511-5-8-.04 Screening Examinations

- (1) The health authority shall use a standardized inspection or test approved by the Department.
- (2) The health authority shall cause staff who will perform the screening examinations to attend training courses offered by the Department as such attendance is deemed necessary by the health authority.
- (3) Volunteers may be utilized by the health authority to assist in the screening program, provided that such persons successfully complete a training course provided by the health authority. The health authority shall certify such persons to the school authority as authorized to participate in the screening program.

Authority: O.C.G.A. Secs. 31-2A-6, 20-2-772. History: Original Rule entitled "Screening Examinations" adopted. F. Oct. 15, 2013; eff. Nov. 4, 2013.

511-5-8-.05 Screening Process

- (1) The health authority shall cause each eligible child to be screened.
- (2) Children identified as having a possible spinal deformity by volunteers shall be rescreened by the health authority.
- (3) The health authority, at its discretion, may conduct follow-up clinics, utilizing x-ray and physician evaluation.
- (4) Parents or guardians shall be notified solely by the health authority if their child is identified, during the screening process, as having a possible spinal deformity. The health authority shall also recommend to the parents or guardians that they seek further professional attention for the child.
- (5) The health authority shall contact parents or guardians, who have been notified that their child may have a possible spinal deformity, to ascertain the outcome of subsequent evaluations.

Authority: O.C.G.A. Secs. 31-2A-6, 20-2-772. History: Original Rule entitled "Screening Process" adopted. F. Oct. 15, 2013; eff. Nov. 4, 2013.

511-5-8-.06 Records and Reports

- (1) The health authority shall submit or cause to be submitted an annual report to the Department. A copy of the annual report shall be provided to the appropriate school authority. The report shall be on forms provided by the Department.
- (2) The health authority shall maintain the names of children screened and the results of their screening pursuant to the schedules developed under the Georgia Records Act.

Authority: O.C.G.A. Secs. 31-2A-6, 20-2-772. History: Original Rule entitled "Records and Reports" adopted F. Oct. 15, 2013; eff. Nov. 4, 2013.

Description

Scoliosis is a physical condition characterized by a sideways curvature of the spine greater than 10 degrees determined by a spinal X-ray.

Most cases are idiopathic, which means the cause is unknown.

AIS accounts for 85 percent of the cases of idiopathic scoliosis. Thus, scoliosis is most often seen in the middle school-age group, when rapid growth is occurring. Girls and boys can be affected.

Scoliosis screening is a clinical process, designed to identify children who have early signs of scoliosis. The goal is to provide timely follow-up and conservative medical treatment before the curve progresses and may require surgery. The American Academy of Orthopaedic Surgeons (AAOS), Scoliosis Research Society (SRS), Pediatric Orthopaedic Society of North America (POSNA) and the American Academy of Pediatrics (AAP) agree that effective clinical scoliosis screening programs provide the opportunity to recognize signs of the condition and make referrals for appropriate medical care.

After scoliosis is identified or suspected, follow-up is essential to measure the degree of curvature and determine treatment options. A spinal X-ray is used to determine the degree of curvature.

Current treatment options consist of medical observation, spinal orthotics (bracing) and corrective surgery. Medical observation includes checkups at designated intervals until the skeleton has reached adult height or skeletal maturity. The goal of orthotic intervention is to keep the curve from progressing until skeletally mature. Corrective surgery is indicated if the curve is progressive and is only needed in severe cases. Current research is focused on understanding the development of idiopathic scoliosis and identifying additional modalities that may provide beneficial treatment options and interventions.

Kyphosis, an accentuated outward curve, or rounding, of the upper back and lordosis, or swayback, may occur independently or in conjunction with scoliosis.

Establishing a school screening program

The person responsible for the school district's scoliosis screening program will coordinate activities with administration, teachers, parents, nurses and screeners.

- Coordinate with school administration.
 - Provide scoliosis screening background information to school system personnel, including:
 - Administrators
 - School nurses
 - Clinic workers
 - Student representatives
 - Others involved in the screening process
 - If needed, review:
 - The legal requirements for scoliosis screening
 - Scope of the problem
 - Rationale and technique of screening
 - Discuss the grades to be screened and methodology for screening.
 - Individual state law governs parameters for scoliosis screening, including the screening process and which grade levels will be screened and the process. Exact ages and grade levels to screen will vary depending on state law, grade structure

of schools and school preference.

- Identify the grades to be screened and the follow-up plan for positive screenings.
- Verify screeners are trained.
- Arrange for untrained health workers to attend an educational scoliosis screening workshop.
 - You may choose to have two or more adults participate in the screening process for security or liability concerns.
- Assistants can help with student preparation and management.
- Determine screening date and site.
 - Schedule the screening so that there are no conflicts with testing, field trips, etc.
 - Possible class times for screening include P.E. or exploratory periods.

Notification of parents

Send out a screening letter or consent form (see appendix) two weeks prior to the screening date(s).

- Enclose the scoliosis screening information, Fast Facts About Scoliosis, available in English and Spanish (see appendix). Visit choa.org/scoliosis to download the forms.
- Instruct teachers to collect and save Do Not Screen forms.

Publicize the screening program on the school website, PTA, student groups and a parent letter (see appendix).

Notification of students

Conduct orientation sessions for each class of students to be screened.

- Show educational "Scoli What?" video on choa.org/scoliosis that explains the importance of scoliosis screening to students.
- Allay any fears the students may have.

Preparation

Determine the amount of time needed to conduct the screenings based on student enrollment minus written parent requests for exemption from screening.

- With an assistant, an experienced screener should be able to screen 20 to 30 students in an hour.

On the day before the scheduled scoliosis screening, remind the students of the screening's purpose.

- Remind the girls to wear a bathing suit top, halter top or sports bra.
- Speak positively.

Have a roster of students available.

- Students whose parents have submitted a request for exemption are excused from screening.
 - Appropriate personnel should be notified privately concerning these students.

Designated screening area

- Check the designated screening area at least one week prior to screening to help make sure the cleanliness of the area and that all lights are in working order. Rechecking one day prior is also recommended.
- Provide privacy for individual screening.
 - Use of screens is encouraged.
 - Cover windows.
 - Locate other students in a designated area where they cannot see their peers being screened.
- Place tape on the floor to indicate where student should stand.
- Provide a place for students to place their shirt or top during screening.
- Make sure the room is well-lit.
- Keep the room's temperature comfortable, as students will be removing shirts or tops.
- Provide a chair, small table or clipboard, and pen for screener.
- Consider placing a horizontal masking tape line on the back wall to check for uneven shoulders.
- Check that the floor is free of uneven areas.

Day of screening

- Student completes demographic section of screening form or the school may provide preprinted labels with required information (see appendix).
- Child should remove shoes during the screening.
- Record the name of each student screened, or use a class roster.
- Note absences on the class roster.

Recording

- Screener records findings on screening form (see appendix).
- Document reasons for exclusion on school health record.

Rescreening (if applicable)

State regulations may require rescreening to verify initial screening findings.

- If secondary screeners were not present at the primary screenings, arrange to rescreen positive or abnormal findings within two weeks.
 - Have the child remove shoes for second screening.
 - Document the second screening on the screening form.
 - Document the second screening results on the school health record.
- Arrange to screen those students who missed initial screening at that time.
 - Document the screening results.
 - Rescreen students with positive findings, if applicable.
- If possible, call parents to explain findings as a courtesy.
 - Explain that signs of scoliosis were noted.
 - These signs indicated that the child needs to be checked by his doctor.
 - Assure the parents that although follow-up is needed, only the physician will determine if the child has scoliosis.
 - Children do not usually have pain associated with signs of scoliosis.
 - Written notification is required and will be forthcoming.

Follow-up activities

- Referral process
 - Provide written notification of a possible spinal deformity to the parent or guardian (see example in the appendix).
 - Written referral letter is the responsibility of the healthcare professional at the screening.
- Maintain the names of children screened and the results.
- Document
 - All findings, positive and negative, should be recorded on the student’s cumulative health record.
 - For positive findings, additional referral information and results of medical evaluations should be recorded.
- Follow-up
 - If parents or guardians do not submit the results of the medical evaluation in writing, the designated health professional shall contact them to ascertain the outcome of the medical evaluation.
 - Discussion of the child-specific signs of scoliosis can be helpful to allay fears and reinforce the need for completing the evaluation process.
- Provide in-school support for those children diagnosed with scoliosis, such as:
 - Adaptation of physical education classes
 - Supervision of brace care
 - Counseling of child and parent or guardian related to prescribed treatment plan
 - Is the child returning for rechecks (observation) at prescribed intervals?
 - Is the child wearing brace as prescribed?
 - Is the child experiencing difficulties?
 - Possible consultation with a physical therapist
 - Education of peers and staff regarding child’s specific needs
- School health professional may develop an individualized healthcare plan (see resources).
- Submit annual report to the designated state agency, as required by state mandates.

Materials needed

- Computer with DVD capability
- LCD projector
- "Curve Checks" DVD
- Pretest forms—one per participant (see appendix)
- Evaluation forms—one per participant (see appendix)
- Curve Checks Reference Guide—one per participant (copy if needed to provide one for each professional)
- Screening form—one per participant (see appendix)
- "Curve Checks" DVD quiz sheet—one per participant (see appendix)
- "Curve Checks" DVD quiz answer key—one per participant (see appendix)
- Practicum form (see appendix)
- Scenarios form (see appendix)

How to use this section

- Scoliosis Screening for Healthcare Professionals is a PowerPoint presentation designed for the instructor's use.
 - The PowerPoint presentation within the manual provides note pages to guide the instructor regarding information on each slide. Note pages contain instructions for the instructor and suggested verbal information to share with other healthcare professionals.
- Download to prepare for training:
 - Powerpoint presentation from choa.org/scoliosis
 - "Curve Checks" DVD
- Handouts can also be printed from the PowerPoint rather than using the Curve Checks Reference Guide.
 - Go to *Adobe/File/Print*. Under Page Sizing & Handling section choose Multiple pages per sheet. Adjust Pages per sheet to number of slides desired.
- As an instructor, preview the DVD with note pages to determine the chapters that are applicable to your healthcare professionals and timeframe.

Scoliosis screening for healthcare professionals



Slide 1

- Prior to class, download the Scoliosis Screening for Healthcare Professionals PowerPoint presentation.
- As healthcare professionals enter the room, pass out the following materials:
 - Pretest–healthcare professionals can take the test prior to beginning the presentation
 - Curve Checks Reference Guide–ask them to review Page 1
 - Screening form
 - DVD quiz sheet
 - DVD quiz answer key (if reference guide not available)
 - Practicum form
 - Scenarios form

Introductions

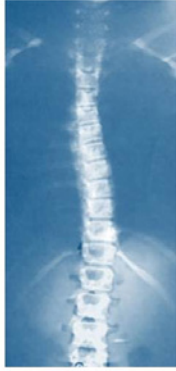

Slide 2

- Introduce yourself and anyone else teaching the class.
- Tell participants something about yourself as it relates to your role and experience with scoliosis screening.
 - How long have you been screening children for scoliosis?
 - Explain your special interest in scoliosis screening.

Overview of scoliosis

- Description and definition



Children's Healthcare of Atlanta



3

Slide 3

Description: Scoliosis is a lateral or sideways deviation or curve from the normal vertical line sagittal plane of the spine, which when measured by X-ray is greater than 10 degrees. This X-ray shows a curve of 9 degrees.

Overview of scoliosis

Myths ☹️

1. Back pain is an indicator for idiopathic scoliosis.
2. Backpacks cause scoliosis.
3. Bad bedding can cause scoliosis.
4. Bad posture causes scoliosis.

Facts 😊

1. Adolescent Idiopathic Scoliosis has few symptoms.
2. 30 percent of families have a history of scoliosis.
3. Scoliosis affects 2 to 3 percent of the adolescent population.
4. Vertebrae changes are multifactorial.

Children's Healthcare of Atlanta



4

Slide 4

Myth 1. Back pain is an indicator for idiopathic scoliosis.

Fact: AIS has few physical symptoms. Back pain is not usually associated with AIS, but pain may be caused by other conditions.

Myth 2. Backpacks cause scoliosis.

Fact: Scoliosis runs in families.

Myth 3. Bad bedding can cause scoliosis.

Fact: Scoliosis affects 2 to 3 percent of the adolescent population.

Myth 4. Bad posture causes scoliosis.

Fact: Vertebrae shape change is due to interrelated physical responses not yet fully understood.

Overview of scoliosis

- Statistics
- Consequences of untreated scoliosis
- Treatments
 - Observation
 - Orthopaedic intervention
 - Orthotics (spinal brace)
 - Surgery

Slide 5

Statistics:

- 2 to 3 percent of the population has scoliosis
- 0.5 percent need orthopaedic intervention

Consequences of untreated scoliosis:

- Back pain
- Cosmetic concerns regarding the way clothing hangs on the body
- Surgical complexity due to positioning and decreased lung function
- High treatment costs related to surgery and postoperative management

Treatments:

- Observation or recheck by physician of adolescents with curves until they reach adult height or skeletal maturity
- Orthopaedic intervention, including bracing (orthotics)
 - A spinal brace is prescribed when the curve reaches about 20 to 25 degrees. It is worn under clothes or at night during the adolescent growth period.
 - The goal of orthotics is to prevent the curve from progressing and to avoid surgical correction.
 - Surgery may be needed if the curve progresses beyond 47 degrees.

Orthopaedic management related to X-rays

- Curve Checks Reference Guide, Page 3
 - 9 degrees
 - 15 degrees
 - 26 degrees
 - 30/30 degrees
 - 52/30 degrees
 - 85 degrees

Slide 6

Let's review some X-rays to relate degrees of curve to orthopaedic management:

Turn to Page 3 in the Curve Checks Reference Guide.

- 9-degree curve: Spinal asymmetry. The body can tolerate this small degree of curve without consequences.
- 15-degree curve: Orthopaedic observation begins. Periodic rechecks are required by the orthopaedic specialist.
- 26-degree curve: Orthopaedic intervention begins. This may include orthotics or brace treatment. The goal of intervention is to keep the curve from progressing.
- 30-degree double curve: Curves of 30 degrees or more are at risk for progression even after skeletal maturity. These curves will need orthopaedic intervention during adolescence with periodic observation throughout adulthood.
- 52-degree thoracic curve with compensatory 30-degree curve: Surgical correction is indicated. This curve will probably progress over the adult lifetime if not surgically corrected.
- 85-degree thoracic curve: Results in decreased pulmonary function and patients experience shortness of breath. Can you see the difference in the rib cage when you look at the right and left side of the ribs?
- Adults with curves of 30 degrees or more may experience back pain, osteoarthritis of the spine and potential significant deformity if curve increases.

Overview of scoliosis

- Types of scoliosis
 - Congenital
 - Neuromuscular
 - Idiopathic
 - Mechanical
 - Other

Children's Healthcare of Atlanta



7

Slide 7

Types

- Congenital–Bony abnormalities of the spine present at birth.
- Neuromuscular–Scoliosis is a secondary diagnosis due to a condition related to the central nervous system, such as cerebral palsy, muscular dystrophy or spina bifida.
- Idiopathic–The cause has not yet been determined.
- Mechanical–Associated with a condition that may initially manifest as scoliosis, however, underlying cause is another condition such as leg-length discrepancy.
- Other–Associated with bone tumors or infections that present as a curvature with pain.

Conditions associated with scoliosis

- Neurofibromatosis
- Down's syndrome
- History of thoracotomy for esophageal atresia, cardiac and pulmonary disorders
- Prader-Willi syndrome
- Noonan syndrome
- Osteogenesis imperfecta
- Pectus excavatum and pectus carinatum
- Klippel-Feil syndrome
- Sprengel's deformity
- Chiara malformation
- Marfan's syndrome

Children's Healthcare of Atlanta



8

Slide 8

Here is a list of conditions that are associated with scoliosis. As healthcare professionals, it is important to be aware of these associated conditions.

- Neurofibromatosis
- Down's syndrome
- History of thoracotomy for esophageal atresia, cardiac and pulmonary disorders
- Prader-Willi syndrome
- Noonan syndrome
- Osteogenesis imperfecta
- Pectus excavatum and Pectus carinatum
- Klippel-Feil syndrome
- Sprengel's deformity
- Chiara malformation
- Marfan's syndrome

“Curve Checks” DVD

- What is scoliosis?
- What causes scoliosis?
- Why is screening important?
- How is scoliosis treated?
- What is my role as a screener?
- Screening preparation

Children's Healthcare of Atlanta



9

Slide 9

Explain to healthcare professionals: "Curve Checks" DVD is designed to give you background information about scoliosis and teach you how to screen. You can follow along in your Curve Checks Reference Guide or watch the video.

- Play the "Curve Checks" DVD—Chapter 1 (Introduction) to Chapter 7 (Screening Preparation).
- Pause DVD.

Observe a screening

- Chapter 8, Normal Screening, Daniella

Slide 10

Hand out the screening form or have participants pull the screening form from their packet. Explain to healthcare professionals that we are ready to review a normal screening.

- Play Chapter 8 (Daniella).

After DVD plays, the instructor may pause the video if there is time and discuss kyphosis as noted in Daniella's screening.

- Daniella is normal until she turns to side and the C curve is not within normal limits.
- She has a sharp angulation or abnormal contour, which is not easily seen in the video.
- Note that in the anterior view, the child's right is on the opposite side as you look at the child. In the posterior view, the right of the child is on your right.

Inform the participants whether the children to be screened have seen the "Scoli What?" video on choa.org/scoliosis as an introduction to scoliosis and what is expected of them during the screening.

- "Scoli What?" is a six-minute video for adolescents to give them information about scoliosis and to show them how to stand and bend during the screening.
- If "Scoli What?" has not been shown, inform the participants that the students may need additional instruction and coaching through the screening process.

5 steps to scoliosis screening

- Receive the screening form from the child
 - Review form
 - Check that demographic information is complete
 - Or
 - Preprinted label is attached

Slide 11

The child will give you the screening form. The demographic portion will be completed. Check the form to see that the demographic section is fully completed.

As you screen the child, you will check any abnormalities you note. You will sign the form and indicate your status: healthcare professional, school nurse, etc.

5 steps to scoliosis screening

- Greet the child by name
 - Shoes off for screening
- Ask the child to
 - Step up to the line.
 - Put your feet together, weight equally on both legs.
 - Take a breath in. Let it out and let your arms hang naturally at your sides.

Slide 12

Greet the child by name.

– Instruct child to remove shoes for the screening.

Instruct the child to:

– Step up to the line.

– Put your feet together, weight equally on both legs.

– Take a breath in. Breathe out and let your arms hang naturally at your sides.


Check to make sure the child is standing correctly. The inner ankle bones (medial malleolus) should be touching. If the child cannot put his feet together, he can stand with his feet slightly apart. Make sure the inner malleoli at the ankle or hindfoot are aligned.

5 steps to scoliosis screening

- Step 1: Anterior view

- Observe for truncal asymmetry:

- Shoulder height asymmetry at lateral end of clavicle
- Unequal distance between arms and torso—one arm hangs out from torso more than the other
- Uneven pelvis—one hip appears higher/more prominent than the other



Children's Healthcare of Atlanta  13

Slide 13

Observe the lateral ends (outside ends) of the clavicle.

Check for shoulder height asymmetry. On the screening form, check the higher shoulder.

Check for unequal distance between the arms and torso. Check and note the arm that hangs out further from the body.

Does the pelvis appear uneven? On the screening form check the side of the pelvis that appears higher. To visualize pelvic asymmetry you may ask the child to put his hands on the top of his hips.

5 steps to scoliosis screening

- Step 2: Adams Forward Bend Test

Instruct child:

- Put the palms of your hands together, arms out straight.
- Put your chin on your chest. Roll down until hands touch your feet.



Children's Healthcare of Atlanta  14

Slide 14

Instruct the child to:

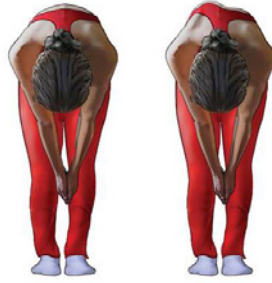- Put the palms of your hands together, arms out straight.
- Put your chin on your chest.
- Keep your knees straight and roll down until your hands touch your feet.

The student's back should be parallel to the floor.

5 steps to scoliosis screening

- Step 2: Continued

- Observe for torso asymmetry
 - Upper thoracic prominence
 - Lower thoracic prominence
 - Lumbar prominence



Children's Healthcare of Atlanta  15

Slide 15

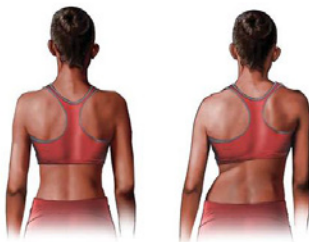Look for:

- High thoracic prominence
- Low thoracic prominence
- Lumbar prominence

Mark screening form if prominence is noted and which side is higher.

5 steps to scoliosis screening

- **Step 3: Posterior view**
- Instruct Child: Turn around and put your toes on the line, weight equally on both legs. Take a breath in. Let it out, and let your arms hang at your sides.
- **Observe for truncal asymmetry:**
 - Asymmetry of shoulders
 - Scapula prominence and/or asymmetry
 - Waist crease asymmetry
 - Unequal distance of arms to torso
 - Spinal curvature



Children's Healthcare of Atlanta  16

Slide 16

Ask the child to turn around.

Give the following instructions:

- Put your feet together, weight equally on both legs.
- Take a breath in.
- Breathe out, and let your arms hang at your sides.

Recheck to make sure the child is standing correctly—the inner malleoli or hindfoot are aligned.

Check for shoulder height asymmetry. On the screening form, check the higher shoulder.

Check for scapular prominence or asymmetry. On the screening form, check the higher or more prominent scapula.

Check for waist-crease asymmetry or no waist crease on one side. On the screening form, note the side of the deeper waist crease.

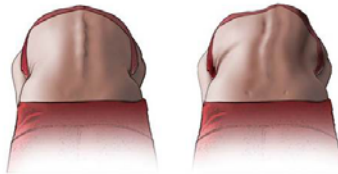
Check to see if one arm hangs out farther from the torso. On the screening form, note the arm that hangs out further from the torso.

Check for a visible spinal curvature.

Check for a truncal shift—C7T1 aligns with gluteal cleft.

5 steps to scoliosis screening

- **Step 4: Bending away**
- Instruct child: Put the palms of your hands together, arms out straight. Put your chin on your chest. Roll down until your hands touch your feet.
- **Observe for truncal asymmetry:**
 - Upper thoracic prominence
 - Lower thoracic prominence
 - Lumbar prominence



Children's Healthcare of Atlanta  17

Slide 17

Instruct the child to:

- Put the palms of your hands together, arms out straight.
- Put your chin on your chest.
- Roll down until your hands touch your feet.

The student's back should be parallel to the floor.

Look for:

- High thoracic prominence
- Low thoracic prominence
- Lumbar prominence

Mark the screening form if prominence is noted and which side is higher.

5 steps to scoliosis screening

- Step 5: Sagittal view
- Instruct child: Turn to the side and put your feet together. Put the palms of your hands together, arms out straight. Put your chin on your chest. Roll down until hands touch your feet.
- Look for sharp angle—
abnormal contour in lower
thoracic area (kyphosis)



Children's Healthcare of Atlanta  18

Slide 18

Instruct the child to:

- Turn to your side, feet together.
- Put the palms of your hands together, arms out straight.
- Put your chin on your chest.
- Roll down until your hands touch your feet.

The student's back should be parallel to the floor.

Observe for sharp angulation and abnormal contour (kyphosis). Note sharp angulation on the screening form.

Thank the child for coming.

Questions

Children's Healthcare of Atlanta  19

Slide 19

Ask participants if they have any questions regarding the five-step process.

“Curve Checks” DVD

- Chapters 9 through 14, Screening Children
 - Karlena
 - Erin
 - Brittany
 - Christopher
 - Alexis
 - Valentina
- “Curve Checks” DVD quiz

Slide 20

Pass out "Curve Checks" DVD quizzes to participants.

Explain to healthcare professionals: Here is an opportunity to practice. Let's watch the DVD and circle positive findings on the quiz sheet. The DVD is a 2-D presentation. In real life, the screening is 3-D, therefore makes it easier to visualize differences.

Return to DVD: Play Chapter 9 (Karlena) through Chapter 14 (Valentina), or play each chapter one at a time and then discuss.

Karlena: Classic signs of thoracic scoliosis—right shoulder elevation, right scapula elevation, right thoracic prominence.

Erin: Negative exam or no signs of scoliosis until viewing lower back or lumbar area. This is why it is important to carefully check the lumbar area.

Brittany: Possible hip height difference, or pelvic asymmetry. Thoracic prominence in posterior view but not in the anterior. Refer child. She also has lumbar prominence.

Christopher: Notice the importance of rolling the scapula off the ribs in the back to get a good view.

Alexis: It is important to make sure she positions her feet properly; she appears nervous. She also needs to be encouraged to roll down further to see her lumbar area. Although the screening is inconsistent with regards to arm and torso distance in the anterior view and the posterior view, she has additional positive signs that indicate she should be referred. If there is time, the screener can repeat the positioning in the anterior and posterior views.

Valentina: Due to the 2-D DVD presentation, it is hard to visualize the findings. In a real screening, this will be easier to see.

Questions

Slide 21

Pass out quiz answer key, or have participants turn to Page 9 in Curve Checks Reference Guide.

- Ask screeners if they have questions.
- Screeners will note recommendation as negative or referral for positive screening results.

"Curve Checks" DVD

- Chapter 15, Your Job is Important

Slide 22

Play Chapter 15 of "Curve Checks" DVD.

Documentation—screener

- Mark abnormal findings on screening form.
 - Anterior view
 - Posterior view
 - Sagittal view
 - Check negative or positive
 - Print name
 - Check category of screener's credentials
 - Record any concerns

Slide 23

Once the screening is complete, check whether it was negative (no abnormal findings) or positive.

- Print your name.
- Check the category of screener based on your credentials.
- Under screener notes, record any concerns—a mole, large abrasion, pustule, burn or large bruise.
- Let the school authority at the screening know if you have concerns.

Discuss the process for how screeners should report concerns on the day of the screening.

Demonstration and/or practice

- Demonstration of practicum
- Practicum
- Screening scenarios

Slide 24

Demonstrate how to use the practicum form.

- As the instructor, you can review a screening using volunteers from the present healthcare professionals as a screener and coach.

Practicum

- You may also have healthcare professionals practice on each other.
 - Divide into small groups of three—screener, screenee and coach.
 - Use practicum form from the appendix.
- Walk around the room to see if participants have questions regarding the screening steps.

Scenarios

- Have participants fill out screening scenarios form.
 - Review each screening scenario.

Screening scenarios

Screening No. 1—Katie

- *In front position:*
 - Shoulders are even
 - Arm hangs out from body more on left
 - Hips appear even
- *As she bends forward:*
 - No rib prominence
 - No lumbar prominence
- *In back position:*
 - Shoulders are even
 - Scapulae are even
 - Waist fold is slightly deeper on left
 - Left arm hangs out from her body
- *As she bends forward:*
 - Slight rib prominence on right
 - No lumbar prominence
- *In side view:* C-shaped curve
- **Is she a positive screen?** **Yes** **No**

Slide 25

Katie is a positive screen for scoliosis.

She needs to be referred for a positive screening.

Screening scenarios

Screening No. 4—Katie

- **In front position:**
 - Shoulders are even
 - Arm hangs out from body more on left
 - Hips appear even
- **As she bends forward:**
 - No rib prominence
 - No lumbar prominence
- **In back position:**
 - Shoulders are even
 - Scapulae are even
 - Waist fold is slightly deeper on left
 - Left arm hangs out from her body
- **As she bends forward:**
 - Slight rib prominence on right
 - No lumbar prominence
- **In side view:**
 - C-shaped curve
- **Is she a referral?** Yes No
- **Why or why not?** _____

Children's Healthcare of Atlanta  26

Slide 26

Reviewing her screening, the positive signs of scoliosis are:

– Anterior position:

Her arm hangs farther out from her body on left.

– Posterior position:

Her waist folds slightly deeper on the left.

Her arm hangs farther out from her body on the left.

There is a slight rib prominence on right.

Yes, she is a referral for a positive screening.

Why:

She has positive signs, including a rib prominence noted in the posterior position.

A rib or lumbar prominence may only be seen in either the anterior or posterior position. It may be easier to see in one position over the other. It does not need to be seen in both positions to be considered a positive screening and referral.

Screening is not a diagnosis. Screening notes signs that need further investigation.

If you have time, you can ask the child to repeat the positioning of the feet and the Adams Forward Bend Test in both positions.

Screening scenarios

Screening No. 2—Alonzo

- **In front position:**
 - Shoulders are even
 - Arms hang evenly from body
 - Right hip appear higher than left
 - With hands on hips — right hip appears higher
- **As he bends forward:**
 - Right lumbar prominence
- **In back position:**
 - Difficulty maintaining correct feet position
 - Shoulders are even
 - Scapulae are even
 - Waist folds are even
 - Arms hang evenly at his sides
- **As he bends forward:**
 - No prominence
- **In side view:**
 - C-shaped curve
- **Is he a positive screen? ___ Yes ___ No**

Children's Healthcare of Atlanta



27

Slide 27

Alonzo is a positive screening for hip height difference and lumbar prominence in the anterior position.

Screening scenarios

Screening No. 2—Alonzo

- **In front position:**
 - Shoulders are even
 - Arms hang evenly from body
 - Right hip appear higher than Left
 - With hands on hips – right hip appears higher
- **As he bends forward:**
 - Right lumbar prominence
- **In back position:**
 - Difficulty maintaining correct feet position
 - Shoulders are even
 - Scapulae are even
 - Waist folds are even
 - Arms hang evenly at his sides
- **As he bends forward:**
 - No prominence
- **In side view:**
 - C-shaped curve
- **Is he a referral? Yes No**
- **Why or why not? _____**

Slide 28

Yes, he is a positive referral notification.

Why:

Hip height difference can cause a lumbar prominence. This is the category of mechanical scoliosis.

He needs a referral because the hip height difference may need treatment. The younger he is, and therefore the less mature his skeleton, the more he is at risk for developing increased hip height difference or increased leg length difference. When the skeleton is immature, there is a window of time when hip height difference can be treated, or he might have lumbar scoliosis and the hip height difference may be minimal.

He needs to be seen by a pediatric orthopaedic physician for an evaluation of these findings.

Screening scenarios

Screening No. 2—Samantha

- **In front position:**
 - Right shoulder higher than left
 - Arms hang evenly from body
 - Hips appear even
- **As she bends forward:**
 - Right rib prominence
 - Lumbar area is even
- **In back position:**
 - Shoulders are even
 - Right scapula is elevated & more pronounced
 - Waist folds are even
 - Arms hang evenly from body
- **As she bends forward:**
 - Right rib prominence
 - No lumbar prominence
- **In side view:**
 - C-shaped curve
- **Is she a positive screen? ___Yes___ No**

Slide 29

Samantha is a positive screen for scoliosis.

She has a rib prominence on the right in both the anterior and posterior positions.

Screening scenarios

Screening No. 2—Samantha

- **In front position:**
 - **Right shoulder higher than left**
 - Arms hang evenly from body
 - Hips appear even
- **As she bends forward:**
 - **Right rib prominence**
 - Lumbar area is even
- **In back position:**
 - Shoulders are even
 - **Right scapula is elevated and more pronounced**
 - Waist folds are even
 - Arms hang evenly from body
- **As she bends forward:**
 - **Right rib prominence**
 - No lumbar prominence
- **In side view:**
 - C-shaped curve
- **Is she a referral?** **Yes** **No**
- **Why or why not?** _____

Children's Healthcare of Atlanta



30

Slide 30

Yes, she is a positive screening notification.

Why:

Although in the anterior position, her shoulders are uneven and in the posterior position her shoulders are even, she has a rib prominence in both positions, and scapula asymmetry in the posterior position.

Screening scenarios

Screening No. 4—Nikolas

- *In front position:*
 - Shoulders are even
 - Arms hang evenly from body
 - Hips appear even
- *As he bends forward:*
 - Left rib elevation
 - Left lumbar elevation
- *In back position:*
 - Left shoulder elevation
 - Left scapulae elevation
 - Waist folds are even
 - Arms hang evenly at his sides
- *As he bends forward:*
 - Left rib elevation
 - Then a right rib elevation
 - Then a left lumbar elevation
- *In side view:*
 - C-shaped curve
- **Is he a positive screen? Yes No**



Slide 31

Nikolas is a positive screen for scoliosis.

Screening scenarios

Screening No. 4—Nikolas

- *In front position:*
 - Shoulders are even
 - Arms hang evenly from body
 - Hips appear even
- *As he bends forward:*
 - Left thoracic elevation
 - Left lumbar elevation
- *In back position:*
 - Left shoulder elevation
 - Left scapulae elevation
 - Waist folds are even
 - Arms hang evenly at his sides
- *As he bends forward:*
 - Left thoracic elevation
 - Then a right thoracic elevation
 - Then a left lumbar elevation
- *In side view:*
 - C-shaped curve
- *Is he a referral?* Yes No
- *Why or why not?* _____

Children's Healthcare of Atlanta



32

Slide 32

Yes, Nikolas needs a referral.

Why:

He may very well have three curves, an atypical curvature pattern. This can be more difficult to treat.

Screening scenarios

Screening No. 5—Madison

- *In front position:*
 - Shoulders are even
 - Arms hang evenly from body
 - Hips appear even
- *As she bends forward:*
 - No rib prominence
 - No lumbar prominence
- *In back position:*
 - Shoulders are even
 - Scapulae are even
 - Waist folds are even
 - Arms hang evenly from body
- *As she bends forward:*
 - No rib elevation
 - No lumbar prominence
- *In side view:*
 - C-shaped curve
- **Is she a positive screen? ___ Yes ___ No**

Slide 33

Madison is a negative screen for scoliosis.

Screening scenarios

Screening No. 5—Madison

- *In front position:*
 - Shoulders are even
 - Arms hang evenly from body
 - Hips appear even
- *As she bends forward:*
 - No rib prominence
 - No lumbar prominence
- *In back position:*
 - Shoulders are even
 - Scapulae are even
 - Waist folds are even
 - Arms hang evenly from body
- *As she bends forward:*
 - No rib elevation
 - No lumbar prominence
- *In side view:*
 - C-shaped curve
- *Is she a referral?* Yes No
- *Why or why not?* _____

Children's Healthcare of Atlanta  34

Slide 34

No, she does not need a referral.

Notes:

The examples today have been more positive screenings for instructional purposes.

We have discussed more positives than negatives today.

In the real world of screening, it will be the other way around, more negatives than positives.

When screening there should be about a 5 percent positive referral rate (range of 4 to 6 percent).

Screening scenarios

Screening No. 6—Jacob

- *In front position:*
 - Shoulders are even
 - Arms hang evenly from body
 - Hips appear even
- *As he bends forward:*
 - No rib prominence
 - No lumbar prominence
- *In back position:*
 - Shoulders are even
 - Arms hang evenly from body
 - Waist folds are even
 - Arms hang evenly at his sides
- *As he bends forward:*
 - No rib prominence,
 - No lumbar prominence
- *In side view:*
 - Hump in the middle of his back
- **Is he a positive screen? ___Yes___No**

Slide 35

Jacob is a positive screen for sagittal plane deformity.

He has a prominence, rather than a C-shaped curve.

In the sagittal plane, you may also notice that the tragus, the flap of cartilage in front of the ear is anterior to the shoulder.

Screening scenarios

Screening No. 6—Jacob

- *In front position:*
 - Shoulders are even
 - Arms hang evenly from body
 - Hips appear even
- *As he bends forward:*
 - No rib prominence
 - No lumbar prominence
- *In back position:*
 - Shoulders are even
 - Arms hang evenly from body
 - Waist folds are even
 - Arms hang evenly at his sides
- *As he bends forward:*
 - No rib prominence
 - No lumbar prominence
- *In side view:*
 - Prominence in the middle of his back
- *Is he a referral?* Yes No
- *Why or why not?* _____

Children's Healthcare of Atlanta



36

Slide 36

Yes, he needs a referral.

Why:

This is known as Scheuermann's kyphosis.

The prevalence of kyphosis is 2.8 percent, a little less than three percent in the population.

The male to female ratio is 2:1, so it is seen twice as often in males when compared to females. It can cause deformity and pain.

Additional screenings—"Curve Checks" DVD

- Jasmine
- Mahogany

Slide 37

See screening scenarios form.

Review the findings:

- Jasmine needs to be encouraged to roll down. She has more subtle signs that are not as easy to note on the 2-D DVD.
- Mahogany also needs to be encouraged to roll down because you can miss her lumbar prominence. You might need to ask her to repeat the roll down (Adams forward bend test).

Ask participants if they have any questions.

Screenings in our school

- Accommodations related to our school
- Dates of screening

Slide 38

School accommodations

Tell participants of any accommodations they should be aware of regarding your school such as:

- Where the children will be screened
- Where the children will put their shirts while being screened
- Dates of screenings

Thank you

- Thank you for coming and learning how to screen adolescents for scoliosis.

Slide 39

Thank your participants.

- If you are beginning the screenings, have screeners move to screening area.
- If you are performing the screenings at a later date, give the dates and time of the screenings.

Materials needed

- Computer with DVD capability
- LCD projector
- "Curve Checks" DVD
- Pretest forms—one per participant (see appendix)
- Evaluation forms—one per participant (see appendix)
- Curve Checks Reference Guide—one per participant (copy if needed to provide one for each attendee)
- Screening form—one per participant (see appendix)
- "Curve Checks" DVD quiz sheet—one per participant (see appendix)
- "Curve Checks" DVD quiz answer key—one per participant (see appendix)
- Practicum form (see appendix)
- Scenarios form (see appendix)

How to use this section

- Scoliosis Screening Instruction for Health Workers and Volunteers is a PowerPoint presentation designed for the instructor's use.
 - The PowerPoint presentation within the manual provides note pages to guide the instructor regarding information on each slide. Note pages contain instructions for the instructor and suggested verbal information to share with attendees.
- Download to prepare for training:
 - Powerpoint presentation from choa.org/scoliosis
 - "Curve Checks" DVD
- Handouts can also be printed from the PowerPoint rather than using the Curve Checks Reference Guide.
 - Go to *Adobe/File/Print*. Under *Page Sizing and Handling* section, choose *Multiple pages per sheet*. Adjust *Pages per sheet* to number of slides desired.
- As an instructor, preview the DVD with note pages to determine the chapters that are applicable to your participants and time frame.

Scoliosis screening instruction for health workers and volunteers



Slide 1

- Prior to class, download the Scoliosis Screening Instruction for Health Workers and Volunteers PowerPoint presentation.
- As attendees enter room, pass out the following materials:
 - Pretest—attendees can take the test prior to beginning presentation
 - Curve Checks Reference Guide—ask them to review Page 1
 - Screening form
 - DVD quiz sheet
 - DVD quiz answer key (if reference guide not available)
 - Practicum form
 - Scenarios form

Introductions

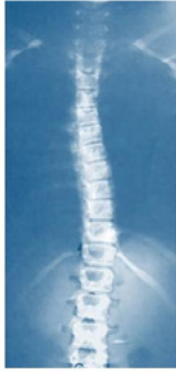

Slide 2

- Introduce yourself and anyone else teaching class.
- Tell participants something about yourself as it relates to your role and experience with scoliosis screening.
 - How long have you been screening children for scoliosis?
 - Explain your special interest in scoliosis screening.

Overview of scoliosis

- Description and definition



Children's Healthcare of Atlanta  3

Slide 3

Description: Scoliosis is a lateral or sideways deviation or curve from the normal vertical line of the spine, which measured by X-ray is greater than 10 degrees. This X-ray shows a curve of 9 degrees.

Overview of scoliosis

Myths ☹️

1. Back pain is an indicator for idiopathic scoliosis.
2. Backpacks cause scoliosis.
3. Bad bedding can cause scoliosis.
4. Bad posture causes scoliosis.

Facts 😊

1. Adolescent idiopathic scoliosis has few symptoms.
2. 30 percent of families have a history of scoliosis.
3. Scoliosis affects 2 to 3 percent of adolescent population.
4. Vertebrae changes are multifactorial.

Children's Healthcare of Atlanta  4

Slide 4

Myth 1. Back pain is an indicator for idiopathic scoliosis.

Fact: AIS has few physical symptoms. Back pain is not usually associated with AIS, but pain may be caused by other conditions.

Myth 2. Backpacks cause scoliosis.

Fact: Scoliosis runs in families.

Myth 3. Bad bedding can cause scoliosis.

Fact: Scoliosis affects 2 to 3 percent of the adolescent population.

Myth 4. Bad posture causes scoliosis.

Fact: Vertebrae shape change is due to interrelated physical responses not yet fully understood.

Overview of scoliosis

- Statistics
- Consequences of untreated scoliosis
- Treatments
 - Observation
 - Orthopaedic intervention
 - Orthotics (spinal brace)
 - Surgery

Slide 5

Statistics:

- 2 to 3 percent of the population has scoliosis.
- 0.5 percent need orthopaedic intervention.

Consequences of untreated scoliosis:

- Back pain
- Cosmetic concerns regarding the way clothing hangs on the body
- Surgical complexity due to positioning and decreased lung function
- High treatment costs related to surgery and postoperative management

Treatments:

- Observation or recheck by physician of adolescents with curves until they reach adult height or skeletal maturity
- Orthopaedic intervention including bracing (orthotics)
 - A spinal brace is prescribed when the curve reaches about 20 to 25 degrees. It is worn under clothes or at night during the adolescent growth period.
 - The goal of orthotics is to prevent the curve from progressing and to avoid surgical correction.
 - Surgery may be needed if the curve progresses beyond 47 degrees.

Orthopaedic management related to X-rays

- Curve Checks Reference Guide, Page 3
 - 9 degrees
 - 15 degrees
 - 26 degrees
 - 30/30 degrees
 - 52/30 degrees
 - 85 degrees

Slide 6

Let's review some X-rays to relate degrees of curve to orthopaedic management:

Turn to Page 3 in the Curve Checks Reference Guide.

- 9-degree curve: Spinal asymmetry. The body can tolerate this small degree of curve without consequences.
- 15-degree curve: Orthopaedic observation begins. Periodic rechecks are required by the orthopaedic specialist.
- 26-degree curve: Orthopaedic intervention begins. This may include orthotics or brace treatment. The goal of intervention is to keep the curve from progressing.
- 30-degree double curve: Curves of 30 degrees or more are at risk for progression even after skeletal maturity. These curves will need orthopaedic intervention during adolescence with periodic observation throughout adulthood.
- 52-degree thoracic curve with compensatory 30-degree curve: Surgical correction is indicated. This curve will probably progress over the adult lifetime if not surgically corrected.
- 85-degree thoracic curve: Results in decreased pulmonary function and patients experience shortness of breath. Can you see the difference in the rib cage when you look at the right and left side of the ribs?
- Adults with curves of 30 degrees or more may experience back pain, osteoarthritis of the spine and potential significant deformity if curve increases.

Overview of scoliosis

- Types of scoliosis
 - Congenital
 - Neuromuscular
 - Idiopathic
 - Mechanical
 - Other

Slide 7

Types

- Congenital–Bony abnormalities of the spine present at birth.
- Neuromuscular–Scoliosis is a secondary diagnosis due to a condition related to the central nervous system, such as cerebral palsy, muscular dystrophy or spina bifida.
- Idiopathic–The cause has not yet been determined.
- Mechanical–Associated with a condition that may initially manifest as scoliosis, however underlying cause is another condition such as leg-length discrepancy.
- Other–Associated with bone tumors or infections that present as a curvature with pain.

"Curve Checks" DVD

- What is scoliosis?
- What causes scoliosis?
- Why is screening important?
- How is scoliosis treated?
- What is my role as a screener?
- Screening preparation

Slide 8

Explain to participants: "Curve Checks" DVD is designed to give you background information about scoliosis and teach you how to screen. You can follow along in your "Curve Checks" Reference Guide or watch the video.

- Play the "Curve Checks" DVD–Chapter 1 (Introduction) to Chapter 7 (Screening Preparation)
- Pause DVD

Observe a screening

- Chapter 8, Normal Screening, Daniella

Slide 9

Hand out screening form or have participants pull screening form from packet. Explain to attendees that we are ready to review a normal screening.

- Play Chapter 8 (Daniella).

After DVD plays, the trainer may pause the video if there is time and may discuss kyphosis as noted in Daniella's screening.

- Daniella is normal until she turns to side and the C curve is not within normal limits.
- She has a hump, which is not easily seen in the video.
- Note that in the front view, the child's right is on the opposite side as you look at the child. In the back view, the right of the child is on your right.

Inform the participants whether the children to be screened have seen the "Scoli What?" video on choa.org/scoliosis as an introduction to scoliosis and what is expected of them during the screening.

- "Scoli What?" is a 6-minute video for adolescents to give them information about scoliosis and to show them how to stand and bend during the screening.
- If "Scoli What?" has not been shown, inform the participants that the students in this school may need additional instruction and coaching through the screening process.

5 steps to scoliosis screening

- Receive the screening form from the child
 - Review form
 - Check that demographic information is complete
 - Or
 - Preprinted label is attached

Slide 10

The child will give you the screening form. The demographic portion will be completed. Check the form to see that the demographic section is fully completed.

As you screen the child, you will check any abnormalities you note. You will sign the form and indicate your status: volunteer, healthcare professional, school nurse, etc.

5 steps to scoliosis screening

- Greet the child by name
 - Shoes on for primary screening
 - Shoes off for secondary screening
- Ask the child to:
 - Step up to the line

 - Put your feet together, weight equally on both legs

 - Take a breath in. Let it out and let your arms hang naturally at your sides

Slide 11

Greet the child by name.

- Shoes may remain on for primary screening; however, instruct child to remove shoes for the secondary screening.

Instruct the child to:

- Step up to the line.
- Put your feet together, weight equally on both legs
- Take a breath in. Breathe out and let your arms hang naturally at your sides.


Check to make sure the child is standing correctly. The inner ankle bones (medial malleolus) should be touching. If the child cannot put his feet together, he can stand with his feet slightly apart. Make sure the inner ankle bones are aligned.

5 steps to scoliosis screening

- Step : Front view

- Observe for:

- Shoulder elevation
- Unequal distance between arms and body—one arm hangs out from body more than the other
- Uneven hips—one hip appears higher than the other



Children's Healthcare of Atlanta  12

Slide 12

Observe the end points (outside edge) of the shoulders (outside ends of clavicle). See if the shoulders are even.

Check if one shoulder is higher and which shoulder is higher, left or right. On the screening form, check the higher shoulder.

Does one arm hang out farther from the body than the other so that there is more space at the waist on one side of the body than the other? Check and note the arm that hangs out further from the body.

Does one hip appear higher than the other? On the screening form check the hip that appears higher.

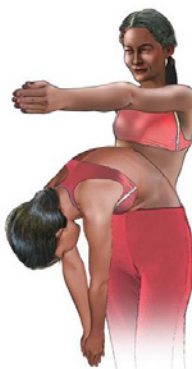To visualize the hip height you may ask the child to put his hands on the top of his hips.

5 steps to scoliosis screening

- Step 2: Adams Forward Bend Test

Instruct child:

- Put the palms of your hands together, arms out straight
- Put your chin on your chest. Roll down until hands touch your feet



Children's Healthcare of Atlanta  13

Slide 13

Instruct the child to:

- Put the palms of your hands together, arms out straight.
- Put your chin on your chest.
- Keep your knees straight and roll down until your hands touch your feet

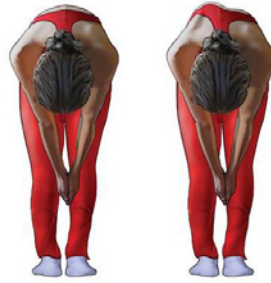The student's back should be parallel to the floor.

5 steps to scoliosis screening

- Step 2: Continued

- Observe for

- Upper rib prominence
- Lower rib prominence
- Lower back (lumbar) prominence



Children's Healthcare of Atlanta  14

Slide 14

Look for:

- High rib prominence
- Low rib prominence
- Lumbar prominence or low back prominence

Mark screening form if prominence is noted and which side is higher.

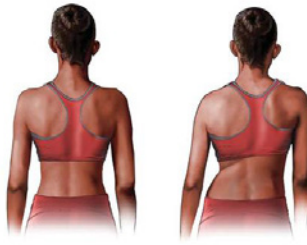5 steps to scoliosis screening

- **Step 3: Back view**

- Instruct Child: Turn around and put your toes on the line, weight equally on both legs. Take a breath in. Let it out, and let your arms hang at your sides

- **Observe for:**

- Uneven shoulders
- Shoulder blade difference
 - Elevation and/or prominence
- Waist fold difference
- Unequal distance of arms to body



Children's Healthcare of Atlanta  15

Slide 15

Ask the child to turn around.

Give the following instructions:

- Put your feet together, weight equally on both legs.
- Take a breath in.
- Breathe out, and let your arms hang at your sides.

Recheck to make sure the child is standing correctly—the inner ankle bones are touching or in alignment.

Check if one shoulder is higher and which shoulder is higher, left or right. On the screening form, check the higher shoulder.

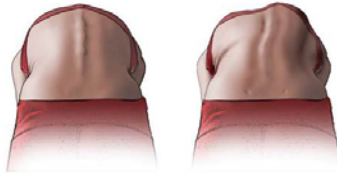
Check if one shoulder blade is higher or more prominent than the other. On the screening form, check the higher or more prominent shoulder blade.

Check if the waist fold is deeper on one side of the body. On the screening form, note the side of the deeper waist fold.

Check to see if one arm hangs out farther from the body. On the screening form, note the arm that hangs out further from the body.

5 steps to scoliosis screening

- Step 4: Bending away
- Instruct child: Put the palms of your hands together, arms out straight. Put your chin on your chest. Roll down until your hands touch your feet
- Observe for:
 - Upper rib prominence
 - Lower rib prominence
 - Lower back (lumbar) prominence



Children's Healthcare of Atlanta  16

Slide 16

Instruct the child to:

- Put the palms of your hands together, arms out straight.
- Put your chin on your chest.
- Roll down until your hands touch your feet.

The student's back should be parallel to the floor.

Look for:

- High rib prominence
- Low rib prominence
- Lumbar prominence or low back prominence

Mark the screening form if prominence is noted and which side is higher.

5 steps to scoliosis screening

- Step 5: Side view
- Instruct child: Turn to the side and put your feet together. Put the palms of your hands together, arms out straight. Put your chin on your chest. Roll down until hands touch your feet
- Look for excessive roundness (kyphosis)



Children's Healthcare of Atlanta  17

Slide 17

Instruct the child to:

- Turn to your side, feet together.
- Put the palms of your hands together, arms out straight.
- Put your chin on your chest.
- Roll down until your hands touch your feet.

The student's back should be parallel to the floor.

Observe for excessive roundness (kyphosis). Note excessive roundness on the screening form.

Thank the child for coming.

Questions

Children's Healthcare of Atlanta  18

Slide 18

Ask participants if they have any questions regarding the five-step process.

“Curve Checks” DVD

- Chapters 9 through 14, Screening Children
 - Karlena
 - Erin
 - Brittany
 - Christopher
 - Alexis
 - Valentina
- “Curve Checks” DVD Quiz

Children's Healthcare of Atlanta  19

Slide 19

Pass out “Curve Checks” DVD quizzes to participants.

Explain to attendees: Here is an opportunity to practice. Let’s watch the DVD and circle positive findings on the quiz sheet. The DVD is a 2-D presentation. In real life, the screening is 3-D, therefore makes it easier to visualize differences.

Return to DVD: Play Chapter 9 (Karlena) through Chapter 14 (Valentina), or play each chapter one at a time and then discuss.

Karlena: Classic signs of thoracic scoliosis—right shoulder elevation, right scapula elevation, right rib prominence.

Erin: Negative exam or no signs of scoliosis until viewing lower back or lumbar area. This is why it is important to carefully check the low back area.

Brittany: Possible hip height difference. Thoracic prominence in back view but not in the front. Refer child for second opinion. She also has lumbar prominence.

Christopher: Notice the importance of rolling the wings bones, or scapula, off the ribs in the back to get a good view.

Alexis: It is important to make sure she positions her feet properly; she appears nervous. She also needs to be encouraged to roll down further to see her low back area. Although the screening is inconsistent with regards to arm and body distance in the front view and the back view, she has additional positive signs that indicate she should be referred for a second screening and a positive referral notification letter based on the second screening. If there is time, the screener can repeat the positioning in the front and back views.

Valentina: Due to the 2-D DVD presentation, it is hard to visualize the findings. In a real screening, this will be easier to see.

Questions

Slide 20

Pass out quiz answer key, or have attendees turn to Page 9 in Curve Checks Reference Guide.

- Ask screeners if they have questions.
- Remind first-time screeners and primary screeners that children are screened twice to recheck the findings.
- Secondary screeners will see the primary screening results and rescreen the child documenting the secondary screening results.
- Secondary screeners will note recommendation as negative or referral for positive screening results.

"Curve Checks" DVD

- Chapter 15, Your Job Is Important

Slide 21

Play Chapter 15 of "Curve Checks" DVD.

Documentation, primary screener

- Mark abnormal findings on screening form.
 - Front view
 - Back view
 - Side view
- Primary screener
 - Check negative or refer for second screening
 - Print name
 - Check category of screener's credentials
 - Record any concerns

Children's Healthcare of Atlanta



22

Slide 22

If you are the primary screener, once the screening is complete, check whether it was negative (no abnormal findings), or check refer for second screening.

- Print your name.
- Check the category of screener based on your credentials.
- Under screener notes, record any concerns—a mole, large abrasion, pustule, burn or large bruise.
- Let the school authority at the screening know if you have concerns.

Discuss the process for how screeners should report concerns on the day of the screening.

Documentation, secondary screener

- Mark abnormal findings on screening form.
 - Front view
 - Back view
 - Side view
- Secondary screener:
 - Check negative or referred
 - Print name
 - Check category of screener's credentials
 - Record any concerns

Slide 23

For secondary screeners:

- Instruct child to remove shoes prior to entering secondary screening area.
- Greet the child.
- Review primary screening form.
- Perform five-step screening, guiding the child through the process.
- Note abnormality, if any.
- Check negative or referred.
- Print name.
- Check category of screener based on credentials.
- Make note if needed.
- Document any reasons for difference of screening.

Demonstration and/or practicum

- Demonstration of practicum
- Practicum
- Screening scenarios

Slide 24

Demonstrate how to use the practicum form.

- As the instructor, you can review a screening using volunteers from the present attendees as a screenee and a coach.

Practicum

- You may also have attendees practice on each other.
 - Divide into small groups of three—screener, screenee and coach.
 - Use practicum form from the appendix.
- Walk around the room to see if participants have questions regarding the screening steps.

Scenarios

- Have participants fill out screening scenarios form.
 - Review each screening scenario.

Screening scenarios

Screening No. 1—Katie

- *In front position:*
 - Shoulders are even
 - Arm hangs out from body more on left
 - Hips appear even
- *As she bends forward:*
 - No rib prominence
 - No low back (lumbar) prominence
- *In back position:*
 - Shoulders are even
 - Shoulder blades are even
 - Waist fold is slightly deeper on left
 - Left arm hangs out from her body
- *As she bends forward:*
 - Slight rib prominence on right
 - No low-back (lumbar) prominence
- *In side view:*
 - C-shaped curve
- **Is she a positive screen? Yes No**



Slide 25

Katie is a positive screening for scoliosis.

Screening scenarios

Screening No. 1—Katie

- *In front position:*
 - Shoulders are even
 - Arm hangs out from body more on left
 - Hips appear even
- *As she bends forward:*
 - No rib prominence
 - No low back (lumbar) prominence
- *In back position:*
 - Shoulders are even
 - Shoulder blades are even
 - Waist fold is slightly deeper on left
 - Left arm hangs out from her body
- *As she bends backward:*
 - Slight rib prominence on right
 - No low-back (lumbar) prominence
- *In side view:*
 - C-shaped curve
- *Is she a referral?* Yes No
- *Why or why not?* _____

Children's Healthcare of Atlanta  26

Slide 26

Let's review the positive signs.

In the front position:

- Her arm hangs out from her body more on the left.

In the back position:

- Her waist fold is deeper on the left.
- Her arm hangs out from her body on the left.
- In her rib cage, the right side is higher than the left.

She needs to be referred for a second screening. Yes, she is a referral for a positive screening for scoliosis.

Why:

She has positive signs including a rib prominence or height difference of the ribs in the Adams forward bend test when she bends forward in the back position.

The prominence does not have to be seen in both positions to be referred for a second screening. It may be easier to see in one position more than the other.

Screening is not a diagnosis. Screening notes signs that need further investigation.

Screening scenarios

Screening No. 2-Alonzo

- *In front position:*
 - Shoulders are even
 - Arms hang evenly from body
 - Right hip appear higher than left
 - With hands on hips – right hip appears higher
- *As he bends forward:*
 - Right low-back (lumbar) prominence
- *In back position:*
 - Difficulty maintaining correct feet position
 - Shoulders are even
 - Scapulae are even
 - Waist folds are even
 - Arms hang evenly at his sides
- *As he bends forward:*
 - No prominence
- *In side view:*
 - C-shaped curve
- **Is he a positive screen? ___ Yes ___ No**



Slide 27

Alonzo is a positive screening for scoliosis.

Screening scenarios

Screening No. 2—Alonzo

- *In front position:*
 - Shoulders are even
 - Arms hang evenly from body
 - Right hip appear higher than left
 - With hands on hips — right hip appears higher
- *As he bends forward:*
 - Right low-back (lumbar) prominence
- *In back position:*
 - Difficulty maintaining correct feet position
 - Shoulders are even
 - Scapulae are even
 - Waist folds are even
 - Arms hang evenly at his sides
- *As he bends forward:*
 - No prominence
- *In side view:*
 - C-shaped curve
- *Is he a referral?* Yes No
- *Why or why not?* _____

Children's Healthcare of Atlanta  28

Slide 28

Let's review his positive signs.

- Alonzo appears to have one hip higher than the other when viewed from the front.
- He also has a prominence in the low back area on the right.

Why:

He needs a referral because the hip height difference may need treatment.

If he is young and therefore he is going to get taller, the leg length difference can become greater as he gets taller.

He may also have low back scoliosis or lumbar scoliosis. He is a positive notification letter to determine what is going on.

Screening scenarios

Screening No. 3—Samantha

- *In front position:*
 - Right shoulder higher than left
 - Arms hang evenly from body
 - Hips appear even
- *As she bends forward:*
 - Right rib prominence
 - Low-back (lumbar) area is even
- *In back position:*
 - Shoulders are even
 - Right shoulder blade is elevated and more pronounced
 - Waist folds are even
 - Arms hang evenly from body
- *As she bends forward:*
 - Right rib prominence
 - No low-back (lumbar) prominence
- *In side view:*
 - C-shaped curve
- **Is she a positive screen? Yes No**

Slide 29

Samantha is a positive screen for scoliosis.

She needs to be screened again to confirm the findings.

Screening scenarios

Screening No. 3—Samantha

- *In front position:*
 - **Right shoulder higher than left**
 - Arms hang evenly from body
 - Hips appear even
- *As she bends forward:*
 - **Right rib prominence**
 - Lower-back (lumbar) area is even
- *In back position:*
 - Shoulders are even
 - **Right shoulder blade is elevated and more pronounced**
 - Waist folds are even
 - Arms hang evenly from body
- *As she bends forward:*
 - **Right rib prominence**
 - No low-back (lumbar) prominence
- *In side view:*
 - C-shaped curve
- **Is she a referral?** **Yes** **No**
- **Why or why not?** _____

Children's Healthcare of Atlanta



30

Slide 30

Let's review her positive signs.

In the front position:

- Her shoulder is higher on the right.
- She has a rib cage that is higher on the right than the left.

In the back position:

- Her shoulder blade is higher on the right.
- Her ribs are higher on the right than the left.

She is a referral because:

She has a rib prominence or chest height difference on one side of her body in both the front position and the back position with shoulder blade differences.

She has classic signs for scoliosis in the rib cage area.

Screening scenarios

Screening No. 4—Nikolas

- *In front position:*
 - Shoulders are even
 - Arms hang evenly from body
 - Hips appear even
- *As he bends forward:*
 - Left rib elevation
 - Left low-back (lumbar) elevation
- *In back position:*
 - Left shoulder elevation
 - Left shoulder blade elevation
 - Waist folds are even
 - Arms hang evenly at his sides
- *As he bends forward:*
 - Left rib elevation
 - Then a right rib elevation
 - Then a left low-back (lumbar) elevation
- *In side view:*
 - C-shaped curve
- **Is he a positive screen?** **Yes** **No**

Children's Healthcare of Atlanta



31

Slide 31

Nikolas is a positive screening for scoliosis.

Nikolas needs to be referred for a second screening.

Screening scenarios

Screening No. 4-Nicholas

- In front position:
 - Shoulders are even
 - Arms hang evenly from body
 - Hips appear even
- As he bends forward:
 - Left rib elevation
 - Left low back (lumbar) elevation
- In back position:
 - Left shoulder elevation
 - Left shoulder blade elevation
 - Waist folds are even
 - Arms hang evenly at his sides
- As he bends forward:
 - Left rib elevation
 - Then a right rib elevation
 - Then a left low back (lumbar) elevation
- In side view: C-shaped curve
- Is he a referral? Yes No
- Why or why not? _____

Children's Healthcare of Atlanta



32

Slide 32

Let's review the positive signs.

In the front position:

- The left rib cage is higher than the right.

In the back position:

- He has a shoulder and shoulder blade elevation with a rib prominence on the same side of his body.
- In the lower rib cage area, there is an elevation on the right.
- He also has a low-back or lumbar prominence on the left.

Nicholas is a referral.

Why:

He has rib prominence on one side in the front and back positions. He also has a low back elevation.

He may well have three curves in his back.

Screening scenarios

Screening No. 5—Madison

- *In front position:*
 - Shoulders are even
 - Arms hang evenly from body
 - Hips appear even
- *As she bends forward:*
 - No rib prominence
 - No low back (lumbar) prominence
- *In back position:*
 - Shoulders are even
 - Shoulder blades are even
 - Waist folds are even
 - Arms hang evenly from body
- *As she bends forward:*
 - No rib elevation
 - No low back (lumbar) prominence
- *In side view:* C-shaped curve
- **Is she a positive screen? ___ Yes ___ No**

Slide 33

Madison is a negative screening for scoliosis.

She does not need to be screened a second time.

Screening scenarios

Screening No. 5—Madison

- **In front position:**
 - Shoulders are even
 - Arms hang evenly from body
 - Hips appear even
- **As she bends forward:**
 - No rib prominence
 - No low-back (lumbar) prominence
- **In back position:**
 - Shoulders are even
 - Shoulder blades are even
 - Waist folds are even
 - Arms hang evenly from body
- **As she bends forward:**
 - No rib elevation
 - No low-back (lumbar) prominence
- **In side view:**
 - C-shaped curve
- **Is she a referral?** Yes No
- **Why or why not?** _____

Slide 34

She does not need a referral.

Notes:

We have discussed more positive screenings than negative screenings today.

The examples today have been more positive screening for instructional purposes.

When you are screening you will probably see more children who do not have signs of scoliosis.

Screening scenarios

Screening No. 6—Jacob

- *In front position:*
 - Shoulders are even
 - Arms hang evenly from body
 - Hips appear even
- *As he bends forward:*
 - No rib prominence
 - No low-back (lumbar) prominence
- *In back position:*
 - Shoulders are even
 - Arms hang evenly from body
 - Waist folds are even
 - Arms hang evenly at his sides
- *As he bends forward:*
 - No rib prominence,
 - No low-back (lumbar) prominence
- *In side view:*
 - Hump in the middle of his back
- **Is he a positive screen? ___Yes___No**

Slide 35

Jacob is a positive screen for scoliosis when we look at him in the side bending position.

Screening scenarios

Screening No. 4—Jacob

- *In front position:*
 - Shoulders are even
 - Arms hang evenly from body
 - Hips appear even
- *As he bends forward:*
 - No rib prominence
 - No low-back (lumbar) prominence
- *In back position:*
 - Shoulders are even
 - Arms hang evenly from body
 - Waist folds are even
 - Arms hang evenly at his sides
- *As he bends forward:*
 - No rib prominence
 - No low-back (lumbar) prominence
- *In side view:*
 - Hump in the middle of his back

Is he a referral? Yes No

Why or why not? _____

Slide 36

He has a hump or prominence in the middle of his back rather than a C-shaped curve.

Why:

This condition called Scheuermann's kyphosis can cause deformity and pain.

Additional screenings—“Curve Checks” DVD

- Jasmine
- Mahogany

Slide 37

Ask: Would you like to see two additional screenings?

Play Chapter 16 (additional screenings) if needed.

Review the findings:

- Jasmine needs to be encouraged to roll down. She has more subtle signs that are not as easy to note on the 2-D DVD.
- Mahogany also needs to be encouraged to roll down because you can miss her low-back prominence. You might need to ask her to repeat the roll down (Adams Forward Bend Test).

Ask attendees if they have any questions.

Screenings in our school

- Accommodations related to our school
- Dates of screening

Slide 38

School accommodations

Tell participants of any accommodations they should be aware of regarding your school such as:

- Where the children will be screened
- Where the children will put their shirts while being screened
- Dates of screenings

Thank you

- Thank you for coming and learning how to screen adolescents for scoliosis.

Slide 39

Thank your participants.

- If you are beginning the screenings, have screeners move to screening area.
- If you are performing the screenings at a later date, give the dates and time of the screenings.

Websites

choa.org/scoliosis (Children’s Healthcare of Atlanta Scoliosis Screening Program)

- Information and videos for parents and adolescents
- Information for healthcare professionals
- Referral forms for physicians

srs.org (Scoliosis Research Society)

- SRS, American Academy of Orthopaedic Surgeons, Pediatric Orthopaedic Society of North America and American Academy of Pediatrics position statement: School Screening Programs for the Early Detection of Scoliosis
- Information about scoliosis conditions and treatment options
- Patient and family information provided in English, Spanish and other languages
- Physician/healthcare professionals tab

nih.gov (National Institutes of Health)

nasn.org (National Association of School Nurses)

niams.nih.gov (National Institute of Arthritis and Musculoskeletal and Skin Diseases)

iscoliosis.com (sponsored by Medtronic, a surgical equipment company)

- Questions regarding scoliosis treatments from families answered by orthopaedic spinal specialists

gdoe.org/curriculum-instruction-and-assessment/ctae/pages/school-nurse.aspx

(Georgia Department of Education)

- Updated information for school nurses regarding current trends and best practices in Georgia

curvygirlsscoliosis.com

- Network and support for girls who are undergoing scoliosis treatment
- National conference and local support groups
- Online discussions

dph.georgia.gov/school-health (Georgia Department of Public Health)

- Updated information pertaining to public health

Financial assistance

Families in need of financial assistance for medical care for their child can contact the following:

- Children’s Medical Services in state of residence
- Child Health Insurance Program in state of residence
- Medicaid in state of residence

Georgia references are provided as a guide:

Department of Community Health regarding Medicaid and PeachCare for Kids

- | | | |
|--------------------------|---|---------------------------------------|
| – Medicaid
dch.ga.gov | – Children’s Medical Services
dph.ga.gov/cms | – PeachCare for Kids
peachcare.org |
|--------------------------|---|---------------------------------------|

Chapter Sixty-two

Scoliosis

Mary Katherine Jessen, Sally Zentner Schoessler

Introduction

Scoliosis is the most common deformity of the spine and is characterized by spinal curvature and rotation (Wilson & Curry, 2011). The child with scoliosis is typically an otherwise healthy child, and the spinal curvature is often an isolated health concern. The cause of scoliosis is often unknown, although it can be congenital, secondary to an underlying neuromuscular disorder, or a compensatory disorder resulting from a discrepancy in the lengths of the child's legs. Scoliosis is most common in adolescents and is classified based on the age of onset (infantile, juvenile, or adolescent).

In 1996, the U.S. Preventive Services Task Force (USPSTF) (2004) recommended against routine screening for scoliosis in the school setting. There was insufficient evidence to prove that early screening of students provided earlier detection, along with significant variability in screening accuracy and poor follow up of positive findings. Based on these recommendations, state requirements for scoliosis screening vary. While some states require scoliosis screening for students annually (8 to 16 years), other states do not make this the responsibility of the school's health services, instead relying on screening during annual childhood physical examinations. As a result of the USPSTF

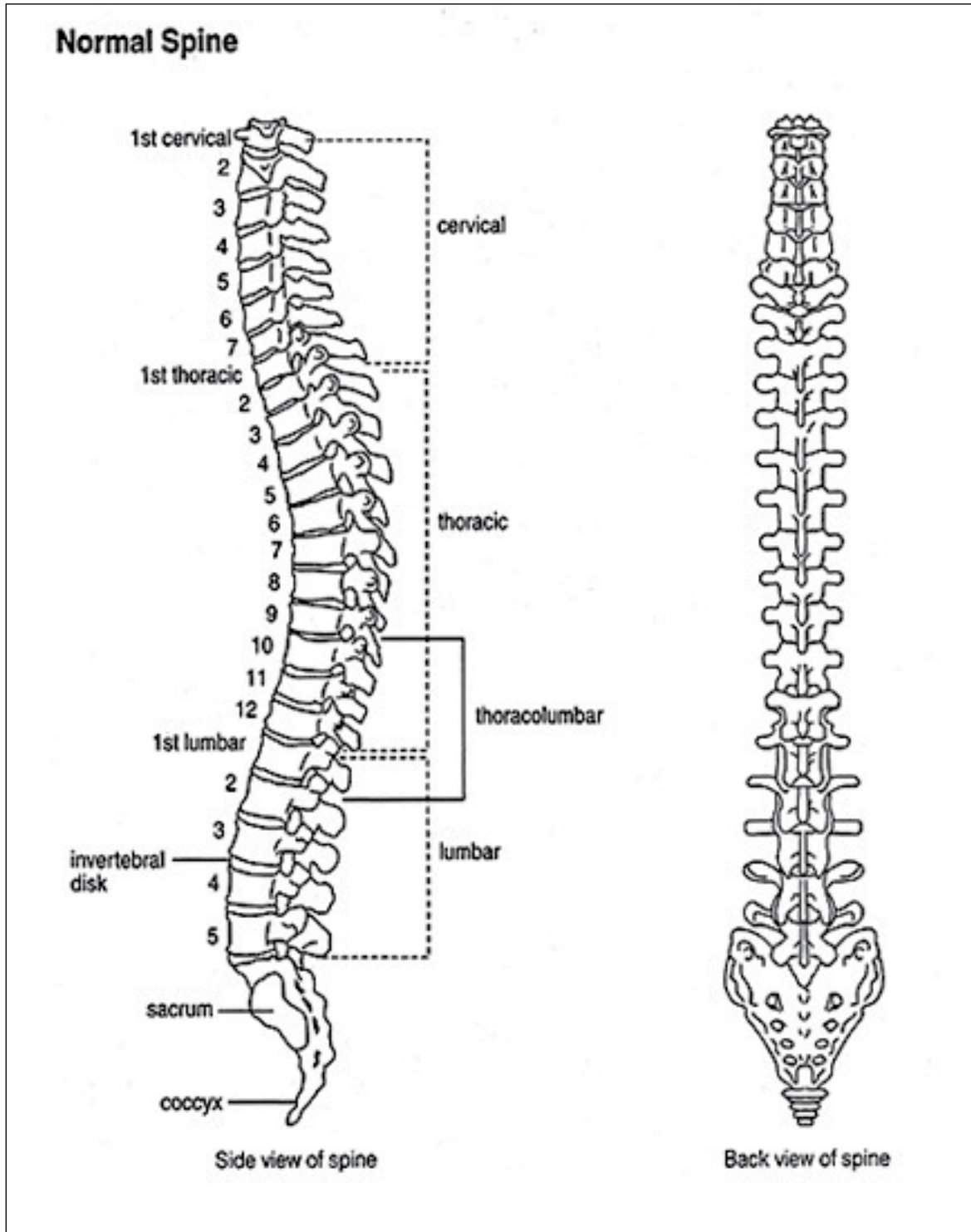
recommendation and the inconsistency in school screening, data have declined and are often very limited or difficult to obtain. However, controversy regarding scoliosis screening persists. Some are concerned that school nurses are already burdened with a significant workload and increasing complex medical care of students in the schools and that preventive screening, timely referrals, and follow up may not be the most efficient use of their time (Jakubowski & Alexy, 2014). On the other hand, the school nurse is able to assess questionable spinal curvatures because he or she has a high level of contact with the student and is able to identify and confirm students at risk for problems related to scoliosis. This is particularly true in identifying individuals with idiopathic scoliosis who may otherwise be overlooked but can benefit from observation or conservative treatment (Fong et al., 2015). Despite the ongoing controversy over population-based screening, Fong et al. (2015) argued that there is still significant benefit, either in the school setting or through routine physicals via a primary healthcare provider. It is also worth noting that the U.S. Preventive Services Task Force (2015) is currently conducting research into the screening of asymptomatic children for scoliosis, with new recommendations to be published in 2017.

Pathophysiology

Scoliosis is defined as a "spinal deformity in three planes, usually involving lateral curvature, spinal rotation causing rib asymmetry, and thoracic kyphosis" (Wilson & Curry, 2011, p.1668). The age of onset and prevalence vary by classification of the condition, though it is usually diagnosed during adolescence, during periods of growth spurts. Two or three percent of the population have idiopathic scoliosis, as well as just over 11% of their first-degree relatives (Giampietro, 2012). Scoliosis can be a stand-alone diagnosis or identified as part of a number of other conditions such as neuromuscular disorders and can be classified as either structural or functional (Negrini

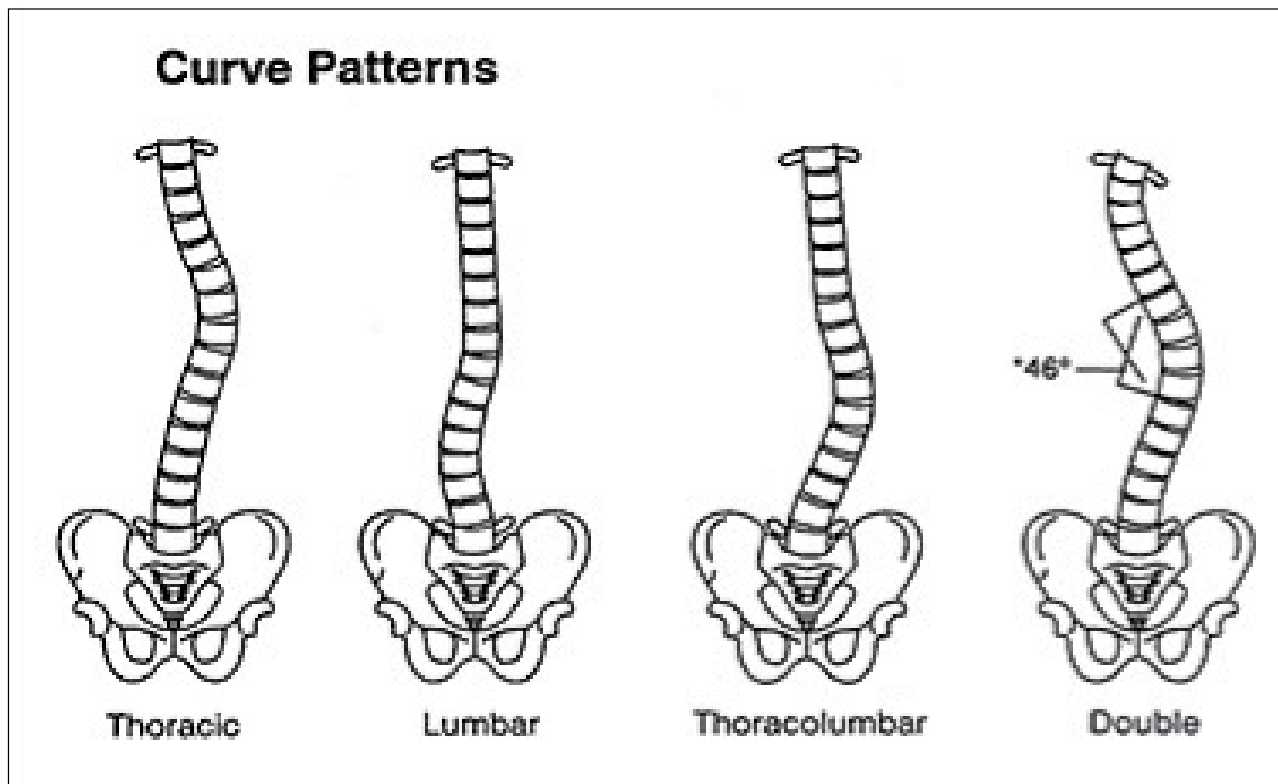
et al., 2012). It is very important that the child is carefully examined to determine the origin and severity of the deformity as well as to determine if there are other related health concerns and the impact of scoliosis on the child's health. Diagnosis is made by direct observation of the child's exposed back and radiographic evaluation, which is used to determine the degree of curvature, as well as to aid in predicting the likelihood of progression (Wilson & Curry, 2011). School accommodations and assistance are based on the severity of the student's condition and any treatments required or necessary adaptive and/or medical equipment.

Figure 1. Diagram of a normal spine



National Institute of Arthritis and Musculoskeletal and Skin Diseases, 2013.

Figure 2. Diagram of curve patterns



National Institute of Arthritis and Musculoskeletal and Skin Diseases, 2013.

Structural Scoliosis

Idiopathic

This is the most common form of scoliosis, with development of the condition occurring most often during growth spurts, with the most rapid progression of curvature happening during puberty (Negrini et al., 2012). Evidence also suggests that there may also be a genetic component. Idiopathic scoliosis is most often diagnosed following a positive finding from school or community health screenings (Wilson & Curry, 2011). The most frequent presenting symptom is back pain at the initial diagnosis, while more symptoms may develop with curvature progression (Altaf, Gibson, Dannawi, & Noordeen, 2013).

Congenital

In congenital scoliosis, spinal abnormalities develop as a result of poor fetal formation or impact to fetal growth during the first trimester (Kaspiris, Grivas, Weiss, & Turnbull, 2011). Symptoms of spinal problems are evident early in the child's life. There can be a partial or complete curvature of the spine, and the scoliosis is often found in combination with other bone or soft tissue anomalies, heart defects, or medical concerns. The risk of progression depends on

many factors specific to the child's overall condition. It is more likely that the student with congenital scoliosis will require accommodations in the school setting than the student with idiopathic scoliosis.

Neuromuscular

Nonidiopathic scoliosis is frequently caused by an underlying neuromuscular disease (Canavese, Rousset, Le Gledic, Samba, & Dimeglio, 2014). These diseases include cerebral palsy, Charcote-Marie-Tooth disease, myelodysplasia, spinal muscular atrophy, Friedrich ataxia, and Duchenne muscular dystrophy. The frequency of occurrence varies with each disease, although as many as 80% to 100% of nonambulatory children develop scoliosis.

Children with neuromuscular scoliosis typically have similar curvatures and patterns of diseases as those with other forms of scoliosis, so treatment options remain the same. However, as a result of the primary neuromuscular disease, the degree of curvature is often greater, and the progression may be more rapid, leading to a decrease in the efficacy of nonsurgical interventions such as spinal orthotics. Surgical interventions also tend to be much more complicated, with high risks of complications and recovery times. Students with neuromuscular scoliosis undergoing

surgical interventions likely require more accommodations and assistance from the school staff to minimize disruptions in their education.

Miscellaneous

In addition to the three most common types of structural scoliosis mentioned previously, other etiologies can include:

- neurofibromatosis;
- spinal trauma (fracture, radiation, or surgical displacement);
- idiopathic spinal symptoms (tumor, inflammation,

nutritional deficit [rickets], metabolic [renal osteodystrophy], and other intraspinal conditions);

- rheumatoid arthritis; and
- congenital disorders (mesenchymal disease, dwarfism, and connective tissue and bone diseases).

Functional scoliosis

Functional scoliosis is caused by a nonspinal condition such as unequal leg length, lack of activity, or poor posture. The curve is flexible, and correction is seen on bending or in compensating for the unequal leg length. However, unlike structural scoliosis, once the underlying issue is corrected, the abnormal curvature disappears.

Management

Treatment of scoliosis depends on several factors, including the age at the time of diagnosis and the degree of curvature. In cases in which the scoliosis is caused by a specific condition, treatment of that underlying condition is necessary to correct the scoliosis. In most cases, treatment begins with the most conservative measures, as appropriate, and progresses based on the etiology, individual's response, and overall complexity of the situation. Left untreated, scoliosis may progress over time, which can impact the individual's daily life and ability to function as an adult. This may include pain, difficulty sitting or standing for prolonged periods, osteoporosis, spinal degeneration, collapsed discs, and even impaired heart and lung function.

Nonoperative

While bracing used to be the gold standard for treatment, it has been found to be variable in effectiveness, due in larger part to a lack of compliance in adolescence (Davies, Norvell, & Hermsmeyer, 2011). The most conservative approach is observation only, in which the student is monitored over time to determine if the curvature is progressing and the impact on the child's daily life. The research is inconclusive on the effects of physical therapy, yoga, and other exercise programs (Mordecai & Dabke, 2012). For students requiring bracing, it is important to note that braces are not necessarily able to correct the curvature; rather, they can hold the spine in correct alignment as the child grows, with a goal of reducing the curvature or preventing progression and thereby possibly eliminating the need for surgical intervention (Davies et al., 2011). The type of brace and duration and frequency of use are determined on a case-by-case basis. Some doctors are finding an

increase in compliance with use of nighttime-only bracing therapy over a longer period.

For children undergoing nonoperative scoliosis treatment, school-based interventions vary. Students may need assistance in scheduling or arranging alternate times for classes or make-up tests to compensate for time missed during the school day due to appointments. Students may come to the clinic on an as-needed basis to rest, for pain medication or, in some situations, to request assistance dealing with skin irritation from the brace.

Operative

Several surgical methods can be employed to straighten and secure the spine (Wilson & Curry, 2011). These often include the implantation of metal rods or a form of spinal fusion to correct the misalignment. Advancements in techniques in recent years have greatly improved outcomes, both in stopping progression and improving spinal alignment, providing an improvement in posture and overall appearance.

Recovery time for these procedures varies and can impact the student's mobility and physical education and/or sports program for up to a full school year. Most students can return to school 2 or 3 weeks after surgery, though some may be on a modified schedule for a time, and some may be out of school for 6 weeks or longer. The nurse and school clinic should work with the student, family, teachers, and medical staff to ensure continuation in the child's education through homebound services, work sent home, and other options as much as possible. All children undergoing spinal surgery to correct scoliosis require pain management and physical therapy and time to readjust to their daily activities and schedules.

Individualized Healthcare Plan (IHP)

It is the responsibility of the registered professional school nurse to develop an IHP and Emergency Action Plan (EAP) for students with healthcare needs that affect or have the potential to affect safe and optimal school attendance and academic performance. The IHP is developed by the school nurse using the nursing process in collaboration with the student, family and healthcare providers. The school nurse utilizes the IHP to provide care coordination, to facilitate the management of the student's health condition in the school setting, to inform school-educational plans, and to promote academic success. The EAP, written by the school nurse, is for support staff with an individual plan for emergency care for the student. These plans are kept confidential yet accessible to appropriate staff. (National Association of School Nurses [NASN], 2015)

Assessment

See *Chapter One: IHP Basics and Using IHPs with Other Educational Health and Home Care Agency Plans* for a comprehensive assessment list.

See the table of contents for other chapters that may contain information relevant to this health condition.

History

- Data/information source: child, parent interviews, and/or medical or school health records
- Medical diagnosis (signs, symptoms, prognosis, history of condition):
 - genetic/inherited disease
 - learning disability
 - scoliosis/related conditions
- Date of diagnosis, curvature attributes, and degree of curvature
- Progression of curvature
- Major illnesses, injuries, hospitalizations, surgeries (including those related to scoliosis)
- Pregnancy, labor and delivery, and neonatal history (gestational age, complications, or tobacco, alcohol, or chemical use)
- Growth history (pattern of growth, any concerns)
- Developmental history (age at which milestones reached)
- Last physical and/or mental health examination, including any radiographic imaging

Current status

- Health care providers, insurance, facilities used
- Data/information source: child, parent interviews, and/or medical or school health records
- Status, symptoms, management plan (note current curvature and other related findings)
- Medical treatments, including use of orthotics, therapies, planned surgeries, and medications
- Activity or mobility limitations
- Allergies
- Body system review (note any concerns in the following areas):
 - general appearance
 - head
 - eyes, ears, nose, throat
 - respiratory
 - cardiovascular
 - gastrointestinal
 - genitourinary
 - musculoskeletal (note activity tolerance and restrictions, limitations, and recommended exercise program)
 - neurological
 - endocrine skin (note issues with skin integrity)
- Sleep patterns
- Elimination/toileting
- Other

Self-care

- Data/information source: child, parent interviews, and/or medical or school health records
- Student's knowledge and understanding of health condition
- Self-care skills, decision-making and problem solving skills, motivation, participation, self-advocacy, and barriers to self-care

- Ability to self-monitor skin integrity, don/doff orthotic independently, identify barriers to self-care, and self-advocate for interventions that could improve self-care, comfort, compliance, and overall well-being
- Compliance with and participation in treatment plan (i.e., therapies, exercises, nonsurgical interventions, use of orthotic devices, postoperative care)

Psychosocial and cultural

- Data/information source: child, parent interviews, and/or medical or school health records
- Mental health (overall cognitive and emotional development and temperament)
- Student strengths and issues related to scoliosis, treatment plan, and impact on life
- Extracurricular activity involvement
- Cognitive, emotional, and social development and temperament
- Cultural or religious beliefs, practices, and considerations
- Family's perception of scoliosis
- Support systems
- Parent/guardian concerns
- Cultural or religious beliefs, practices, and needs

Academic

- Data/information source: child, parent interviews, staff interviews, absenteeism records
- Past and current academic achievement
- School health services needed (medications, specialized school health procedures, and school and classroom modifications)
- Past or current 504 plan
- Past or current special education services, including occupational, physical, and speech/language therapy
- Transportation needs
- Emergency Evacuation Plan
- Equipment needs
- Agencies and organizations involved in the student's care

Nursing Diagnoses (ND) (Herdman & Kamitsuru [Eds.], 2014)

See the front of this book for the complete listing of NANDA Nursing Diagnoses 2015–2017.

ND 1 Impaired physical mobility related to:

- neuromuscular impairment
- musculoskeletal impairment
- pain
- spinal surgery
- use of orthotic brace

ND 2 Risk for activity intolerance related to:

- insufficient physiological energy to complete daily activities
- musculoskeletal abnormalities
- neuromuscular impairment
- use of orthotic brace
- deconditioned state following spinal surgery
- pain
- imposed activity restrictions

ND 3 Chronic pain related to:

- chronic musculoskeletal condition
- neuromuscular impairment
- use of orthotic brace

ND 4 Ineffective breathing pattern related to:

- musculoskeletal impairment
- pain
- fatigue

- anxiety
- body position that inhibits lung expansion
- use of orthotic brace
- spinal surgery

ND 5 Risk for impaired skin integrity related to:

- pressure over bony prominence from orthotic brace
- impaired sitting
- altered body position
- spinal surgery

ND 6 Disturbed body image related to:

- surgical procedure and resulting scarring
- altered body function due to scoliosis
- altered view of one's body/self-perception
- chronic musculoskeletal condition
- use of orthotic brace
- nonacceptance from peers

ND 7 Risk for chronic low self-esteem related to:

- inadequate respect from others
- insufficient feeling of belonging
- pain
- use of orthotic brace
- poor self-image
- perceived differences between self and others

ND 8 Deficient knowledge related to:

- insufficient information
- insufficient interest in learning
- insufficient knowledge of resources
- misinterpretation of information
- lack of understanding regarding positive assessment findings

Nursing Interventions

The school nurse will:

- help parent and student access a healthcare provider as needed for assessment of positive screening findings. (ND 8)
- communicate with healthcare providers and treatment team, with parental permission, to document treatment plan and prognosis for student's condition. (ND 1-5)
- encourage student to identify and discuss activities that are difficult and/or strenuous for him or her due to spinal abnormalities, use of orthotics, spinal surgery and recovery, and activity restrictions and limitations. (ND 1-4)
- encourage student to identify and discuss activities that are pleasurable and manageable for him or her even with activity restrictions and limitations. (ND 1-4, 6, 7)
- collaborate with physical education teachers to modify physical education activities as needed per activity limitations by physician. (ND 1, 2, 3)
- arrange for classroom/school building modifications and accommodations such as extra books, early release between classes and at the end of the day, use of the elevator, and homebound services, as needed per healthcare provider recommendations and limitations. (ND 1-5)
- encourage student to verbalize feelings about body image and self as related to the diagnosis of scoliosis and his or her treatment plan and how it relates to his or her life. (ND 6, 7)
- help student and parents understand the diagnosis of scoliosis and the scoliosis management plan and encourage information seeking and sharing of knowledge regarding: (ND 6, 7, 8)
 - screening procedure
 - screening results
 - pathophysiology of scoliosis
 - treatment options

- personal treatment plan
- school management plan
- use of orthotics prescribed and self-care as related to their use, if appropriate
- surgical procedures and recovery process, if appropriate
- discuss and revise school scoliosis management plan with parents and students, as needed, to provide collaborative student care. (ND 1, 2, 5, 8)
- discuss with student and parent the need to monitor skin integrity and proper care of areas of skin irritation. (ND 5)

Expected Student Outcomes

To make outcomes measurable, add the number of days per week, percentage of time, or specific date, as appropriate to the statement.

The student will:

- attend classes without absences and with minimal impact to learning related to scoliosis symptoms and treatment. (ND 1-4)
- participate in classroom and school activities with modifications as needed. (ND 1-4)
- participate in physical education classes with modifications in activities as needed. (ND 1-4)
- demonstrate proper use of his or her orthotic and use. (ND 1-4, 5, 8)
- express feelings about body image. (ND 6, 7)
- express positive feelings about himself or herself and what he or she is capable of doing well. (ND 1, 2, 6, 7)
- describe scoliosis, his or her treatment plan, and preventive actions and possible complications. (ND 8)
- demonstrate appropriate self-limitation of activities 100% of the time based on scoliosis management plan in physical education classes and sports activities. (ND 1-4)
- express his or her concerns related to the diagnosis, impact on his or her life, and upcoming scoliosis treatments. (ND 6, 7, 8)
- experience minimal skin breakdown due to proper use of orthotic brace, treatment plan compliance, and early identification of issues and appropriate intervention. (ND 5)

Preliminary Individualized Healthcare Plan (IHP)

The purpose of this preliminary IHP is to guide the nurse in developing a concise, initial IHP. For a child with specific health concerns, entering school for the first time or returning after a significant health event, it is imperative that the school nurse completes a nursing assessment to identify any health, emergency, or safety concerns and initiate an IHP. This preliminary IHP provides priority assessment points, nursing diagnoses, interventions, and expected student outcomes to support immediate school attendance with health needs identified and addressed.

The preliminary IHP is then expanded into a more comprehensive IHP based on data from the full nursing assessment. The nursing diagnoses, nursing interventions, and expected student outcomes in this preliminary IHP have been chosen to fit most situations for a student with this health condition. In the preliminary IHP form, space has been included for items not specifically listed yet needing immediate attention. *To make expected student outcomes measurable, add the number of days per week, percentage of the time, or specific date, as appropriate to the statement.* **The nurse is encouraged to expand the preliminary IHP in the very near future in order to care for the student's full range of health concerns requiring attention in the school setting.**

Preliminary Individualized Healthcare Plan

Name _____ D.O.B. _____
Address _____ Homephone _____
Parents/guardians _____ Grade _____
School _____
Healthcare provider(s) _____
Insurance provider _____ ICD-10-CM _____
IEP Date _____ 504 Date _____ EAP Date _____ EEP Date _____

Medical Diagnosis: Scoliosis

Nursing Assessment

See the master list in this chapter and *Chapter One: IHP Basics and Using IHPs with Other Educational, Health and Home Care Agency Plans* for additional assessment points.

- Skin breakdown
- Impaired mobility
- Negative body image
- Fatigue
- Decreased self-confidence
- Activity restrictions

Other: _____

Nursing Diagnoses

- Impaired physical mobility
- Disturbed body image
- Deficient knowledge

Other: _____

Nursing Interventions

The school nurse will:

- communicate with healthcare providers and treatment team to document treatment plan and prognosis.
- arrange for modifications and accommodations per treatment plan recommendations and student limitations.
- encourage student to verbalize feelings about body image and self.
- help student and parents understand the diagnosis and treatment plan.
- discuss and revise school scoliosis management plan with parents and students as needed.

Other: _____

Expected Student Outcomes

The student will:

- attend classes without absences and with minimal impact to learning, as evidenced by attendance record and teacher reports during the current academic term.
- participate in classroom and school activities with modifications as needed, as evidenced by observation, student report, and teacher report.
- demonstrate proper use of his or her orthotic and us as prescribed, as evidenced by verbalization, reciprocal demonstration, observation, and parent/student report between initial receipt of the brace and the next healthcare provider follow-up visit.
- describe scoliosis, his or her treatment plan, and preventive actions and possible complications, as evidenced by verbalization, reciprocal demonstration, school nurse observation, and parent/student report between initial receipt of treatment plan and the next healthcare provider follow-up visit.
- express his or her concerns related to the diagnosis, impact on his or her life, and upcoming scoliosis treatments.

Other: _____

Plan initiated by _____ Date: _____

Case Study

Stephanie, 16, was screened annually for scoliosis from age 8 until the current time. Her screening results were negative until age 12, at which time the school nurse found her to have an 8- to 9-degree thoracic spinal curvature using a scoliometer. A referral was sent home and returned with the report that an orthopedic scoliosis specialist had already seen her after the curvature was noticed by her healthcare provider at her seventh-grade physical. She has had a series of x-rays as well as a computed tomographic scan. At the time of examination, the specialist did not restrict her activity. During a follow-up visit, Stephanie was prescribed a Milwaukee brace and physical therapy to prevent progression of her curvature. However, the restrictive nature of the brace, social stigma, and near-constant use led to low compliance. Her curvature has continued to progress and reached a measurement of greater than 50 degrees. Her parents indicated that they were seeking a second opinion and that she would be evaluated for possible surgical intervention.

In the summer preceding this school year, Stephanie underwent surgery to have a full metal rod inserted along her spine. She has been recuperating in a brace and can expect to wear the brace for 2 to 4 months. A section 504 meeting was held and she was found eligible for accommodations based on her limitations and recommendations from the surgeon, including no physical education classes or sports for the full school year, as well as to avoid lifting heavy objects. It has been arranged to issue her three sets of books so that she will not need to carry any textbooks. She has been given permission to sit in the back of the class to move and adjust her position as needed, and a chair is available in each classroom that she is comfortable sitting in. She has a clinic pass that can be used for periods in which she needs to rest or obtain assistance with pain management. Her doctor has said she may use the stairs, but an elevator pass has been issued for use as she feels the need. She is also allowed to leave class 2 or 3 minutes early to avoid being bumped in the hallway and to allow extra time to navigate between classes.

Case Study IHP

Nursing Assessment	Nursing Diagnoses	Nursing Interventions	Expected Student Outcomes
<p>Stephanie has difficulty ambulating and maneuvering with brace in place at school</p>	<p>Impaired physical mobility related to spinal surgery and use of orthotic brace</p>	<p>Communicate with healthcare providers and treatment team, with parental permission, to document treatment plan and prognosis for Stephanie's condition</p> <p>Encourage Stephanie to identify and discuss activities that are difficult and/or strenuous for her due to use of the orthotic brace, spinal surgery and recovery, and based on activity restrictions and limitations</p> <p>Arrange for a 504 plan that includes classroom/school building modifications and accommodations such as extra books, early release between classes and at the end of the day, and use of the elevator, as needed per healthcare provider recommendations and limitations</p>	<p>Stephanie will attend classes 90% of the time without absences and with minimal impact to learning through the current marking period</p> <p>Stephanie will participate in classroom and school activities with modifications as needed 90% of the time</p> <p>Stephanie will demonstrate appropriate self-limitation of activities based on scoliosis management plan 100% of the time</p>
<p>Stephanie is embarrassed by the attention her brace draws and the postoperative accommodations and restrictions</p> <p>She feels left out by her friends and peers</p>	<p>Disturbed body image related to altered chronic musculoskeletal condition; alteration of body function/physical mobility; use of orthotic brace, surgery; altered view of her body/self-perception; and the disruption to her school schedule</p>	<p>Encourage Stephanie to identify and discuss activities that are pleasurable and manageable for her even with activity restrictions and limitations</p> <p>Encourage Stephanie to verbalize feelings about body image and self as related to the diagnosis of scoliosis and her treatment plan and how it relates to her life</p>	<p>Stephanie will express feelings about body image during each meeting with the school nurse and/or educational team, as needed, over the next 2 months</p> <p>Stephanie will express her concerns related to the diagnosis, impact on her life, and her treatment plan over the next month</p>
<p>Stephanie does not consistently follow through with her treatment plan and often questions the reason behind it</p>	<p>Deficient knowledge related to insufficient information; being unfamiliar with terminology; and resources and misinterpretation of information</p>	<p>Help Stephanie and her parents understand the diagnosis of scoliosis and the scoliosis management plan and encourage information seeking and sharing of knowledge</p> <p>Arrange for a 504 plan for Stephanie and review with student and parents to provide further information and understanding</p>	<p>Stephanie will demonstrate appropriate self-limitation of activities based on scoliosis management plan 100% of the time</p> <p>Stephanie will express her concerns related to the diagnosis, impact on her life, and her treatment plan over the next month</p> <p>Stephanie will accurately describe scoliosis and her treatment plan during the next two meetings with the nurse and/or educational team</p>

Related Services and Supplementary Aids and Services for the Case Study for IEP Billing

The student in this case study does not have an IEP, but if IEP services are initiated, this statement could be used: Nursing service is a necessary related service to assess and monitor the student's health condition/status, communicate with parents and healthcare providers, and provide healthcare planning, medications, and treatments as needed to minimize the impact of the health condition on the attainment of his or her IEP goals (St. Paul Public Schools, 2015).

See these chapters for additional information:

- *Chapter Three: Special Education – Description, Process and Using the IHP Information*
- *Chapter Four: Special Education – Other Health Impairment (OHI)*
- *Chapter Five: Reimbursement for Healthcare Services Provided in Schools*

504 Accommodations for Case Study

Stephanie, 16, has recently undergone corrective spinal surgery for scoliosis. She is currently recuperating in an orthotic back brace, which she will wear for the next 2 to 4 months.

Stephanie's physician has advised that she should not participate in any physical education classes or sports for 1 year and must avoid lifting heavy objects. Due to the nature of her brace and post-surgery discomfort, she requires the ability to move and reposition herself frequently, as well as alternative seating to accommodate the brace. She is progressing well but still finds herself easily fatigued and needing assistance with pain management, necessitating visits to the school nurse and clinic. She is not restricted from using the stairs but may find the elevator easier to help her transition between classes, particularly with crowded hallways and limited time. Due to her mobility limitations, it is often difficult for her to move between classes in the allotted time.

Generally, students with scoliosis require varying levels of accommodations based on the severity of their illness, comorbid conditions, and specific treatment plan. These needs and accommodations may change over time based on complications, healing, and student response to treatment. Accommodations may be classroom-based, such as alternative or adapted equipment to ease the student's discomfort, and allow them to focus on their learning, a reduction in workload or assignments, or issuance of an additional set of textbooks. These students may have a decreased level of activity tolerance or limited physical mobility and may also require assistance and/or extra time to transition between activities or classes. Students may be unable to carry their bag alone or may need an alternative bag. Those with more intensive treatment plans or recovering from surgery may require a reduction in the school day or homebound instruction.

Based on Stephanie's treatment plan, allowances should be made in advance for her to have access to the school nurse or clinic. Stephanie may require assistance or care in terms of pain management, monitoring for complications, rest breaks, or aid with her orthotic device. Depending on the impact of the illness and treatment plan, Stephanie may also have emotional and mental needs that can be addressed through visits to the school counselor or psychologist.

The school nurse will work collaboratively with Stephanie, her parents, her medical team, and school treatment team to ensure that the restrictions and recommendations of the healthcare provider(s) are followed, considering the capabilities of the student. Stephanie's needs will fluctuate over time with the treatment plan, and the nurse will work to ensure that she is able to receive equal access to education and a positive learning environment in the least restrictive ways possible.

504 Accommodations for Case Study

- Allow her preferential seating in the classroom (i.e., sitting in the back for easy entrance/exits, sitting in a place where movement within the classroom is easier and less distracting)
- Give alternative seating type to accommodate brace and positioning postoperatively (i.e., sitting on cushions or chairs instead of the floor, allowing Stephanie to use a chair with a cushion, finding a wider chair or one that is easier for the student to get in and out of)
- Allow Stephanie to get up and move around during class to alleviate discomfort or change positions to avoid impaired skin integrity
- Give Stephanie an additional set of textbooks for home use to lessen the physical burden of carrying them back and forth to school
- Allow Stephanie to use alternative backpack or rolling bag to alleviate strain on back
- Allow for extra time transitioning between classes to avoid being jostled in the hallway and to accommodate for limited mobility
- Provide an elevator pass for Stephanie to lessen strain of transitioning between classes
- Provide alternate physical education curriculum for Stephanie (i.e., written assignments)
- Give pre-approved visits to the school clinic (for assistance with donning/doffing brace, rest breaks, pain management, assistance with skin integrity management)
- Pre-approve visits to the school counselor and/or psychologist as needed if she is having difficulty managing the social, emotional, and mental well-being impact of her diagnosis and treatment plan
- Adjust class schedule postoperatively as needed based on Stephanie's ability to manage current workload
- Pre-approve excused tardy, absent, and/or missed classwork due to medical appointments
- Reduce classroom assignments as needed, based on Stephanie's ability to manage current workload
- Request approval for homebound instruction services, if necessary

See these chapters for additional information:

- *Chapter Two: 504 Plans and Accommodations - Using the IHP Information*
- *Chapter Five: Reimbursement for Healthcare Services Provided in Schools*

Emergency Action Plan (EAP) for Case Study

For his case study, an EAP is not applicable.

Emergency Evacuation Plan (EEP) for Case Study

The school nurse and educational team should be familiar with all standard school emergency evacuation procedures. These guidelines are in addition to such protocols and are designed to reflect the special needs of students who are nonambulatory or have limited mobility.

Emergency Evacuation Plan for Case Study			
Name	___ Stephanie _____	D.O.B.	_____
Address	_____		Homephone _____
Parents/guardians	_____	Grade	_____
School	_____		
Healthcare provider(s)	_____		
Insurance provider	_____	ICD-10-CM	_____
IEP Date	_____ 504 Date _____	EAP Date	_____ EEP Date _____
Medical Diagnosis: Scoliosis			
This student may require assistance during a school emergency that involves school building evacuation. Follow the steps below.			
Before an emergency			
<ul style="list-style-type: none"> • The school nurse and Stephanie's educational team will meet to review the best evacuation routes for her class location and schedule, considering her mobility limitations. • Determine if any special equipment, other than her brace, must accompany Stephanie upon evacuation. Develop a list and update it as necessary. • Identify all accessible exits, areas for shelter in place, and areas where the student can await rescue assistance. • Based on Stephanie's location and the available emergency exits, determine the minimum number of staff needed to assist in an emergency. • Set up an emergency communication plan and personnel responsible for assisting Stephanie. • The written plan will be distributed on a need-to-know basis to her educational team and the school nurse. • The plan will be reviewed with Stephanie, the nurse, and her team, and rehearsed to ensure smooth communication and a safe exit in an emergency. 			
In an emergency			
<ul style="list-style-type: none"> • Only persons who have had appropriate rescue/evacuation training, per the written plan, should assist Stephanie, unless it is a life-threatening situation. • Help clear the exit route of debris so that a clear path is available for evacuation. • Ensure that Stephanie has any necessary medical equipment with her that cannot be left behind. • Be aware, that in most situations, elevators are out of service, and Stephanie must be evacuated via the stairs. • Evaluate the situation to determine if evacuation or shelter in place is the more favorable option for Stephanie based on location and her mobility limitations at the time. • Shelter in place. • It is unlikely that Stephanie would need to shelter in place unless she was experiencing complications or pain further limiting her mobility. However, a plan should be in place in case such a situation arises. • Select a room with an exterior window, telephone, and solid and/or fire-resistant door. • A chosen staff member should remain with Stephanie in this room and send someone to the evacuation assembly area to notify emergency personnel of the location and request for assistance. 			
Evacuating persons with limited mobility			
<ul style="list-style-type: none"> • Even with Stephanie's limited mobility, she can walk, either alone or with assistance, and safely evacuate using the stairs. • Stephanie should be assigned a staff member to assist her during each portion of the school day. In some cases, ancillary school staff or an administrator may be most appropriate. • Stephanie should wait until evacuation traffic has slowed or cleared to begin her exit. This will allow personnel time to clear a path and will enhance her safety as well as that of others. 			
Initiated by School Nurse	_____	Signature	_____ Date _____
<p><i>Although caution has been exercised to develop this EEP template accurately and in accordance with professional standards, the information herein does not serve as a substitute for nursing judgment or professional direction from a physician/advanced practice nurse. It does not outline an exclusive course of treatment and must be individualized to the student's safety needs.</i></p>			

References

- Altaf, F., Gibson, A., Dannawi, Z., & Noordeen, H. (2013). Clinical review: adolescent idiopathic scoliosis. *British Medical Journal*, 346 (f2508), doi: <http://dx.doi.org/10.1136/bmj.f2508>
- Canavese, F., Rousset, M., Le Geldic, B., Samba, A., & Dimeglio, A. (2014). Surgical advances in the treatment of scoliosis. *World Journal of Orthopedics*, 5(2), 124-133, doi: 10.5312/wjo.v5.i2.124
- Davies, E., Norvell, D., & Hermsmeyer, J. (2011). Efficacy of bracing versus observation in the treatment of idiopathic scoliosis. *Evidence-Based Spine-Care Journal*, 2(2), 25-34, doi: 10.1055/s-0030-1267102
- Fong, D. Y. Cheung, K. M., Yong, Y. M., Lee, C. F., Lam, T. P. Cheng, J. C., Ng, B. K., & Luk, K. D. (2015). A population-based cohort study of 394,401 children followed for 10 years exhibits sustained effectiveness of scoliosis screening. *Spine*, 15(5), 825-833, doi: 10.1016/j.spinee.2015.05.01.019
- Giampietro, P. F. (2012). Genetic aspects of congenital and idiopathic scoliosis. *Scientifica*, 2012, article number 152365, 15 pages, doi: 10.6064/2012/152365
- Herdman, T. H., & Kamitsuru, S. (Eds.). 2014. *Nursing diagnoses - Definitions and classification (2015-2017)*. Copyright © 2014, 1994-2014 NANDA International. Used by arrangement with John Wiley & Sons Limited.
- Jakubowski, T. L., & Alexy, T. M. (2014). Does school scoliosis screening make the grade? *NASN School Nurse*, 29(5), 258-65, doi: 10.1177/1942602X14542131
- Kaspiris, A., Grivas, T. B., Weiss, H., & Turnbull, D. (2011). Surgical and conservative treatment of patients with congenital scoliosis: a search for long-term results. *Scoliosis*, 6(12), doi: 10.1186/1748-7161-6-12
- Mordecai, S. C., & Dabke, H. V. (2012). Efficacy of exercise therapy for the treatment of adolescent idiopathic scoliosis: a review of the literature. *European Spine Journal*, 21(3), 382-389, doi: 10.1007/s00586-011-2063-4
- Negrini, S., Aulisa, A. G., Aulisa, L., Circo, A. B., de Mauroy, J.C., Durmala, J., Grivas, T. B., Knott, P., Kotwicki, T., Maruyama, T., Minozzi, S., O'Brien, J.P., Papadopoulos, D., Rigo, M., Rivard, C. H., Romano, M., Wynne, J. H., Villagrasa, M., Weiss, H., & Zaina, F. 2011 SOSORT guidelines: orthopaedic and rehabilitation treatment of idiopathic scoliosis during growth. *Scoliosis*, 7(3), doi: 10.1186/1748-7161-7-3
- National Association of School Nurses. (2015). *Individualized healthcare plans: The role of the school nurse* (Position Statement). Silver Spring, MD: Author. Retrieved from <http://www.nasn.org/PolicyAdvocacy/PositionPapersandReports/NASNPositionStatementsFullView/tabid/462/ArticleId/32/Individualized-Healthcare-Plans-The-Role-of-the-School-Nurse-Revised-January-2015>
- National Institute of Arthritis and Musculoskeletal and Skin Diseases. (2013). *Questions and answers about scoliosis in children and adolescents*. Retrieved from http://www.niams.nih.gov/Health_Info/Scoliosis/#curved
- Saint Paul Public Schools (2015). *Easy IEP, IEP Ed. Plan, Nursing Justification Statements*. Student Health & Wellness, Saint Paul, MN: Author.
- U.S. Preventive Services Task Force (USPSTF) (2004). *Final Recommendation Statement: Idiopathic Scoliosis in Adolescents: Screening, June 2004*. Retrieved from <http://www.uspreventiveservicestaskforce.org/Page/Document/RecommendationStatementFinal/idiopathic-scoliosis-in-adolescents-screening>
- U.S. Preventive Services Task Force (USPSTF) (2015). Adolescent idiopathic scoliosis: screening. *Recommendations in Progress*. Retrieved from <http://www.uspreventiveservicestaskforce.org/Page/Document/UpdateSummaryDraft/adolescent-idiopathic-scoliosis-screening1?ds=1&s=scoliosis>
- Wilson, D., & Curry, M. (2011). The child with musculoskeletal or articular dysfunction. In M. J. Hockenberry & D. Wilson (Eds.). *Wong's nursing care of infants and children* (9th ed.) (pp 1619-1688). St. Louis, MO: Elsevier Mosby.

Resources

American Academy of Orthopedic Surgeons
9400 West Higgins Road
Rosemont, IL 60018
Phone: 847-823-7186
Email: orthoinfo@aaos.org
www.aaos.org
Monthly Journal: *Journal of the American Academy of Orthopedic Surgeons*

Boston Children's Hospital – Spinal Program
School Nurse's Guide to Scoliosis
300 Longwood Avenue
Boston, MA 02115
Phone: 617-355-6021
www.childrenshospital.org/~media/centers-and-services/programs/o_z/spinal-program/scoliosisebook.ashx?la=en

National Association of the State Boards of Education
State School Health Policy Database (for information on scoliosis screening mandates)
333 John Carlyle Street, Suite #530
Alexandria, VA 22314
Phone: 703-684- 4000
www.nasbe.org/healthy_schools/hs/map.php

National Institutes of Health
National Institute of Arthritis and Musculoskeletal and Skin Diseases
1 AMS Circle
Bethesda, MD 20892-3675
Phone: 301-495-4484
Email: NIAMSInfo@nih.mail.gov
www.niams.nih.gov

National Scoliosis Foundation
5 Cabot Place
Stoughton, MA 02072
Phone: 800-673-6922
Email: NSF@scoliosis.org
www.scoliosis.org
Biannual newsletter: *The Spinal Connection*

The Pediatric Orthopedic Society of North America
9400 West Higgins Road
Rosemont, IL 60018
Phone: 847-698-1682
Email: posna@aaos.org
www.posna.org

Scoliosis Research Society
611 East Wells Street, Suite 1100
Milwaukee, WI 53202-3892
Phone: 414-289-9107
Email: info@srs.org
www.srs.org

Forms

Forms included in this section are designed to enhance instruction of volunteers and provide information to parents, volunteers, instructors and professionals involved in scoliosis screening. These forms are available at choa.org/scoliosis.

Materials in this section that may be reproduced as needed:

- Pretest form
- Pretest answer key
- "Curve Checks" DVD quiz
- "Curve Checks" DVD answer key
- Scoliosis Screening Instruction Evaluation
- Scoliosis Screening Practicum Form
- Screening Scenarios Form
- Middle school parent newsletter information
- Notification of screening: Letter to parents (English and Spanish)
- Fast Facts About Scoliosis for parents (English and Spanish)
- Individual Scoliosis Screening Form
- School Screening Log
- Parent Notification of Positive Screening/Referral Form (English and Spanish)
- Adolescent idiopathic scoliosis fact sheet
- Backpack information for parents and students (English and Spanish)
- Five-step scoliosis screening process for volunteers
- Five-step scoliosis screening process for healthcare professionals

Pretest form

1. Scoliosis refers to curves greater than:

- a. 5 degrees
- b. 10 degrees
- c. 20 degrees
- d. 40 degrees

2. Myth (M) or fact (F)?

- a. Scoliosis is mostly idiopathic (having no known cause).
- b. Scoliosis is similar to osteoporosis.
- c. Back pain is a symptom that indicates scoliosis in adolescents.
- d. Bad posture can cause scoliosis.
- e. Backpacks can cause scoliosis.

3. What are signs of scoliosis? (check all that apply)

- a. Uneven shoulders
- b. One hip higher than the other
- c. One arm hangs out farther from the torso
- d. Waist fold difference
- e. Thoracic (rib) prominence
- f. Lumbar (low-back) prominence

4. Why is screening for adolescent idiopathic scoliosis important? (check all that apply)

- a. Screening takes place when children are at risk for developing scoliosis.
- b. Curves need to be found when they are small curves.
- c. Adolescents will have problems in adult life if severe curves are not treated.
- d. All of the above

5. Who determines if the child has scoliosis?

- a. Screener
- b. Parent
- c. Physician

6. Put the steps in the scoliosis screening process in the proper order (note as 1 to 5).

- a. Child faces away from the screener.
- b. Child bends forward.
- c. Child turns to the side and bends forward.
- d. Child faces the screener.
- e. Child bends forward with the child's back to the screener.

Pretest answer key

1. Scoliosis refers to curves greater than:

- a. 5 degrees
- b. 10 degrees
- c. 20 degrees
- d. 40 degrees

2. Myth (M) or fact (F)?

- F a. Scoliosis is mostly idiopathic (having no known cause).
- M b. Scoliosis is similar to osteoporosis.
- M c. Back pain is a symptom that indicates scoliosis in adolescents.
- M d. Bad posture can cause scoliosis.
- M e. Backpacks can cause scoliosis.

3. What are signs of scoliosis? (check all that apply)

- a. Uneven shoulders
- b. One hip higher than the other
- c. One arm hangs out farther from the torso
- d. Waist fold difference
- e. Thoracic (rib) prominence
- f. Lumbar (low-back) prominence

4. Why is screening for adolescent idiopathic scoliosis important? (check all that apply)

- a. Screening takes place when children are at risk for developing scoliosis.
- b. Curves need to be found when they are small curves.
- c. Adolescents will have problems in adult life if severe curves are not treated.
- d. All of the above

5. Who determines if the child has scoliosis?

- a. Screener
- b. Parent
- c. Physician

6. Put the steps in the scoliosis screening process in the proper order (note as 1 to 5).

- 3 a. Child faces away from the screener.
- 2 b. Child bends forward.
- 5 c. Child turns to the side and bends forward.
- 1 d. Child faces the screener.
- 4 e. Child bends forward with the child's back to the screener.

SCOLIOSIS SCREENING INSTRUCTION

DATE: _____

EVALUATION

___ SCHOOL NURSE ___ PUBLIC HEALTH NURSE ___ OTHER
 ___ HEALTHCARE PROFESSIONAL

Overall Evaluation: <i>Please circle the appropriate response:</i>	Strongly Disagree	Disagree	Somewhat Agree	Agree	Strongly Agree
1. The method used to present the material held my attention	1	2	3	4	5
2. The presenters demonstrated mastery of the topic.	1	2	3	4	5
3. The presenters were responsive to participant questions.	1	2	3	4	5
4. Overall, I was satisfied with the quality of this course/program	1	2	3	4	5
5. At the completion of this instruction, I am much more confident in screening children for scoliosis.	1	2	3	4	5
Course Objectives: Overall Skills/knowledge presented met the course objectives <i>Please circle the appropriate response:</i>	Strongly Disagree	Disagree	Somewhat Agree	Agree	Strongly Agree
Distinguish between myths and facts regarding scoliosis.	1	2	3	4	5
Discuss the importance of scoliosis screening for adolescents.	1	2	3	4	5
Describe the scoliosis screening process including all five steps.	1	2	3	4	5
Report the abnormal physical findings of the scoliosis screening.	1	2	3	4	5
Describe the treatment options for scoliosis.	1	2	3	4	5
Presenters: <i>Please circle the appropriate response:</i>	Strongly Disagree	Disagree	Somewhat Agree	Agree	Strongly Agree
_____	1	2	3	4	5
The presenter was effective.	1	2	3	4	5

Name _____ Title _____

Credentials _____

Scoliosis Screening Practicum Form

Check as person named above performs the scoliosis screening process:

____ Reviews documentation form—child's name and date of birth

____ Assesses visual height of child to position self correctly (sitting or standing)

____ Instructs child to position self front standing position

____ 1. Feet in alignment

____ 2. Arms at sides

____ Verbally note physical observations

____ 1. Shoulders uneven/even

____ 2. Unequal distance between arms and body

____ 3. Hip uneven/even

____ Instructs child in Adams Forward Bend Test

____ 1. Palms together, arms out straight

____ 2. Roll down until back parallel to floor

____ Verbally notes physical observations

____ 1. Thoracic prominence

____ 2. Lumbar prominence

____ Instructs child to position self back standing position

____ 1. Feet in alignment

____ 2. Arms at sides

____ Verbally note physical observations

____ 1. Shoulders uneven/even

____ 2. Shoulder blade (scapula) more prominence

____ 3. Shoulder blade elevated

____ 4. Unequal distance between arms and body

____ 5. Waist fold deeper one side

____ Instructs child in Adams Forward Bend Test

____ 1. Palms together, arms out straight

____ 2. Roll down until back parallel to floor

____ Verbally notes physical observations

____ 1. Thoracic prominence

____ 2. Lumbar prominence

____ Instructs child to position self in side position

____ 1. Feet in alignment

____ Instructs child in Adams Forward Bend Test

____ 1. Palms together, arms out straight

____ 2. Roll down until back parallel to floor

____ Verbally notes normal C curve or more than normal roundness

____ Credentials _____ Initials _____

Print name of coach

Date _____

Name _____ Date _____

Title _____

Screening Scenario No. 1

Katie—In the front position, her shoulders are even; her arm hangs out from her body more on her left. Her hips appear even. As she bends forward, no rib or lumbar prominence is seen. In the back position, her shoulders are even, her scapulas are even and her waist fold is slightly deeper on the left. Her left arm hangs out from her body. As she bends forward, a slight rib prominence is noted on the right. In the side position she has a c-shaped curve.

Is she a positive screen? ____Yes ____No

Should she be referred? ____Yes ____No

Screening Scenario No. 2

Alonzo—In the front position, his shoulders are even and his arms hang evenly from his body. His right hip appears higher than his left. When asked to place his hands on his hips, his right hip appears higher than his left. As he rolls down, a right lumbar prominence is noted. In the back position, he seems to have difficulty maintaining the correct feet position, with feet together, weight evenly on both feet. His shoulders are even, his scapulas are even and his waist fold is even, his arms hang evenly at his sides. As he bends forward, no prominence is noted. In the side position he has a c-shaped curve.

Is he a positive screen? ____Yes ____No

Should he be referred? ____Yes ____No

Screening Scenario No. 3

Samantha—In the front position, her right shoulder is higher than her left, her arms hang evenly from her body and her hips appear even. As she bends forward, there is an elevation of her right rib area (asymmetry of rib cage). Her lumbar area is even. In the back position, her shoulders are even, her right scapula is elevated and more pronounced, her waist folds are even and her arms hang evenly from her body. As she bends forward, there is a right rib prominence but no lumbar prominence. In the side position she has a c-shaped curve.

Is she a positive screen? ____Yes ____No

Should she be referred? ____Yes ____No

Screening Scenario No. 4

Nikolas—In the front position, his shoulders are even and his arms hang evenly from the side. His hips are even. As he bends forward, there is a possible left rib elevation and a possible left lumbar elevation. In the back position, his left shoulder and his left scapula are elevated. His waist folds are even. His arms hang out evenly from the side of his trunk. As he bends forward, there appears to be a left rib prominence, then a right rib prominence and then a left lumbar prominence. In the side position he has a c-shaped curve.

Is he a positive screen? ____Yes ____No

Should he be referred? ____Yes ____No

Screening Scenario No. 5

Madison—In the front position, her shoulders are even, her arms hang evenly from her sides, her hips appear even. As she bends forward her ribs appear symmetrical, as is the lumbar area. In the back position, her shoulders are even, her scapulas are even, her arms hang evenly from her side, her waist fold is the same. As she bends forward, there is symmetry in the thoracic and lumbar areas. In the side position she has a c-shaped curve.

Is she a positive screen? Yes No

Should she be referred? Yes No

Screening Scenario No. 6

Jacob—In the front position, his shoulder are even, his arms hang evenly from his sides, his hips appear even. As he bends forward his ribs appear symmetrical, and there is no unevenness in the lumbar area. In the back position, his shoulders are even, his scapulas are even, his arms hang evenly from his side, his waist fold is the same. As he bends forward, there is symmetry in the thoracic and lumbar areas. In the side position, as he bends forward there is a prominence in the middle of his back.

Is he a positive screen? Yes No

Should he be referred? Yes No

Additional screening scenarios from "Curve Checks" DVD, Chapter 16

Screening Scenario No. 7

Jasmine—What do you see as you watch the video?

- | | |
|---|--|
| Front view—Shoulder elevation | <input type="checkbox"/> Left <input type="checkbox"/> Right |
| Unequal distance arm to body | <input type="checkbox"/> Left <input type="checkbox"/> Right |
| Uneven hips | <input type="checkbox"/> Yes <input type="checkbox"/> No |
| Rib prominence | <input type="checkbox"/> Left <input type="checkbox"/> Right |
| Lumbar prominence | <input type="checkbox"/> Left <input type="checkbox"/> Right |
| Back view—Shoulder elevation | <input type="checkbox"/> Left <input type="checkbox"/> Right |
| Shoulder blade elevation or prominence | <input type="checkbox"/> Left <input type="checkbox"/> Right |
| Waist fold difference | <input type="checkbox"/> Yes <input type="checkbox"/> No |
| Unequal distance arm to body | <input type="checkbox"/> Left <input type="checkbox"/> Right |
| Rib prominence | <input type="checkbox"/> Left <input type="checkbox"/> Right |
| Lumbar prominence | <input type="checkbox"/> Left <input type="checkbox"/> Right |
| Side view—More than normal rounded back | <input type="checkbox"/> Yes <input type="checkbox"/> No |

Screening Scenario No. 8

Mahogany–What do you see as you watch the video?

- | | | | | |
|---|-------|------|-------|-------|
| Front view–Shoulder elevation | _____ | Left | _____ | Right |
| Unequal distance arm to body | _____ | Left | _____ | Right |
| Uneven hips | _____ | Yes | _____ | No |
| Rib prominence | _____ | Left | _____ | Right |
| Lumbar prominence | _____ | Left | _____ | Right |
| Back view–Shoulder elevation | _____ | Left | _____ | Right |
| Shoulder blade elevation or prominence | _____ | Left | _____ | Right |
| Waist fold difference | _____ | Yes | _____ | No |
| Unequal distance arm to body | _____ | Left | _____ | Right |
| Rib prominence | _____ | Left | _____ | Right |
| Lumbar prominence | _____ | Left | _____ | Right |
| Side view–More than normal rounded back | _____ | Yes | _____ | No |

SAMPLE

Stay ahead of the curve

During the teenage years, a condition called scoliosis may develop. About 2 to 3 percent of children will develop this condition. The cause is usually not known. Scoliosis is a sideways bending of the spine that can get worse quickly during the teen years. Scoliosis also can make the spine rotate. A curve in the spine can be overlooked until it has become very noticeable. Some children will develop serious problems later in life if the condition is not treated. That is why it is important to have your child checked for scoliosis.

The school will be providing a screening examination as required by Georgia State Law O.C.G.A. Section 20-2-772 to check for this condition. The screening is simple and easy. The children are screened privately by a trained scoliosis screener. You will receive additional information by email or mail about scoliosis, and how and when the screening will be conducted.

Date: _____

Dear parent/guardian:

In the next few weeks, _____ School will conduct a scoliosis screening required by Georgia State Law O.C.G.A. 20-2-772 to identify students with signs of abnormal curvature of the spine. It is known that 2 to 3 percent of children may have scoliosis. If this condition is detected early and appropriately treated, progressive spine deformity can usually be prevented.

The procedure for screening is a simple test in which the trained screener looks at the child's back in the standing position and while bending forward. Boys and girls are screened separately. Girls should wear a bra, sports bra or bathing suit under their clothes on the day of the screening.

If your child has a suspected curvature, you will be notified and asked to take your child to your family doctor for further evaluation. **If you do not want your child to be screened, complete the requested information below and return it to the school.**

Sincerely,

Principal (school administrator)

I DO NOT WANT MY CHILD TO BE SCREENED FOR SCOLIOSIS

My child is currently under care/observation for spinal problems: ____ Yes ____ No

Print name of child

Print name of parent/guardian

Signature of parent/guardian

Date: _____

School: _____

Teacher: _____

Fecha: _____

Estimado padre/tutor:

En las próximas semanas _____ School
llevará a cabo un programa de detección de escoliosis, exigido por el Código 20-2-772 de la Asamblea General de Georgia para identificar a estudiantes con signos de curvatura anormal de la columna vertebral. Se sabe que dos o tres niños de cada 100 pueden tener escoliosis. Si esta condición se detecta a tiempo y se trata de manera adecuada, la deformidad progresiva de la columna vertebral por lo general se puede prevenir.

El procedimiento para la evaluación n es una prueba sencilla en la que el evaluador entrenado mira a la espalda del niño, tanto en la posición de pie y mientras se dobla hacia adelante. Los niños y las niñas son examinados por separado. Las niñas deben usar sostén, sujetador deportivo o traje de baño bajo la ropa el día de la evaluación.

Si su hijo tiene una curvatura sospechosa, se le notificará y se le pedirá llevar a su hijo a su médico de cabecera para que se haga otra evaluación. **Si no quiere que su hijo sea evaluado, por favor complete la información solicitada a continuación y devuélvala a la escuela.**

Atentamente,

Director (administrador de la escuela)

NO QUIERO QUE MI HIJO SEA EVALUADO PARA DETECTAR LA ESCOLIOSIS

Mi hijo está actualmente bajo tratamiento/observación para problemas de columna vertebral: ____ Sí ____ No

Nombre del niño (letra de imprenta)

Nombre del padre/tutor (letra de imprenta)

Firma del padre/tutor

Fecha: _____

Escuela: _____

Maestro: _____

Fast Facts About Scoliosis



What is scoliosis?

Scoliosis is a sideways curve of the spine. Adolescent idiopathic scoliosis (AIS) is the medical name for the most common type of scoliosis. AIS happens in children older than age 10 and teenagers. Idiopathic means that we do not know what causes it.

- The curve can make the spine look more like an “S” or “C” than a straight line when viewed from the back.
- Scoliosis also can make the spine rotate. This can make the shoulders or waist look uneven.

What causes scoliosis?

Scoliosis tends to show up during teenage growth spurts. It also runs in families, but there is no known cause. Scoliosis is not caused by bad posture, heavy backpacks, poor diet or playing sports.

What is a scoliosis screening exam?

The exam will be at your child’s school and done by trained screeners, such as nurses, physical education teachers or parent volunteers.

- The exam will take about one minute to complete.
- Boys and girls are screened separately in private areas. Girls may wear swimsuit tops under their clothes and remove their shirts for screening. Boys will take off their shirts for the exam.

What are the signs of scoliosis?

The screener will look for certain signs during the exam, including:

When your child is standing:

- Uneven shoulders
- One shoulder blade sticking out more than the other

When your child is bending forward:

- A rib hump, called a rib prominence
- A lower back hump called a lumbar prominence

Scoliosis does not usually cause back pain. This is why it is important to look for signs on the outside of the body.

Scoliosis is best treated when found early. It can be hard to tell if your child has scoliosis. It is important for your child to have an exam done by trained screeners in school. More serious treatments for scoliosis can be avoided when scoliosis is found early.

Visit choa.org/scoliosis for more information about the Children’s Healthcare of Atlanta Scoliosis Screening Program.

This is general information and not specific medical advice. Always consult with a doctor or healthcare provider if you have questions or concerns about the health of a child.

Datos importantes sobre la escoliosis

(Fast Facts About Scoliosis)



Children'sSM
Healthcare of Atlanta

¿Qué es escoliosis?

Escoliosis es una curvatura lateral de la columna vertebral. La escoliosis idiopática del adolescente (*Adolescent Idiopathic Scoliosis*, AIS por su nombre y sigla en inglés) es el nombre médico del tipo más común de escoliosis. Ocurre en niños mayores de 10 años y en adolescentes. Idiopática, significa que se desconoce la causa.

- La curvatura hace que la columna se parezca más a una "S" o a una "C" que a una línea recta cuando se observa desde la parte de atrás.
- La escoliosis también puede hacer que la columna rote, lo cual hace que los hombros o la cintura se vean desnivelados.

¿Cuál es la causa de la escoliosis?

La escoliosis tiende a aparecer durante los períodos de crecimiento rápido en la adolescencia. También es hereditaria, pero se desconoce la causa. La escoliosis no es producida por mala postura, mochilas (*backpacks*) pesadas, mala alimentación ni por practicar deportes.

¿Qué es un examen de detección de escoliosis?

El examen lo hacen en la misma escuela de su niño, por personas especialmente capacitadas como enfermeras, profesores de educación física o padres voluntarios.

- El examen se demora aproximadamente un minuto.
- Niños y niñas se examinan separadamente, en áreas privadas. Las niñas pueden usar la parte de arriba de un traje de baño debajo de la ropa, ya que se quitarán la camisa para hacer el examen. Los niños simplemente se quitan la camisa.

¿Cuáles son los posibles signos de escoliosis?

El examinador buscará ciertos signos durante el examen que incluyen:

Cuando su niño está parado:

- Hombros desnivelados
- Un omoplato sobresale más que el otro

Cuando el niño se inclina hacia adelante:

- Una joroba de las costillas, conocida como prominencia de las costillas
- Una joroba de la parte inferior de la espalda, conocida como prominencia lumbar

La escoliosis generalmente no produce dolor de espalda. Por eso es importante buscar signos en el exterior del cuerpo.

La escoliosis se trata mejor cuando se detecta en forma temprana. Puede ser difícil saber si su niño tiene escoliosis. Por eso es importante que un examinador entrenado le haga un examen en la escuela. Cuando la escoliosis se detecta temprano se pueden evitar tratamientos más complejos.

Visite la página de Internet choa.org/scoliosis para obtener más información sobre el Programa de detección de escoliosis de Children's Healthcare of Atlanta.

Esta información es general; no es un consejo médico específico. Si usted tiene alguna pregunta o inquietud acerca del cuidado médico o la salud de su hijo, consulte siempre con su médico u otro profesional de la salud.

SCREENING FORM

Grade (circle): 6 7 8 Other: _____

Primary screening date: ____/____/____ Homeroom: _____

Student's last name: _____ First name: _____ M.I.: _____

Date of birth: ____/____/____ Race/ethnicity: _____ Female Male

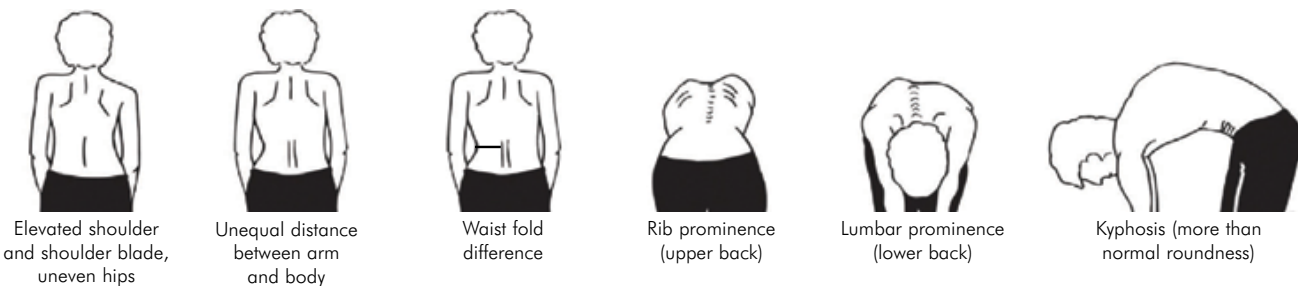
Name of parent/guardian: _____

Address: _____ Apt. #: _____

City: _____ State: _____ Zip: _____

Phones: Home (____) ____-____ Work (____) ____-____ Cell (____) ____-____

Name of school: _____ District: _____



	Primary screener		Secondary screener	
	Left	Right	Left	Right
Front				
Shoulder elevated				
Unequal distance arm to body				
Uneven hips				
Rib prominence				
Lumbar prominence				
Back				
Shoulder elevated				
Shoulder blade elevation/prominence				
Waist fold difference				
Unequal distance arm to body				
Rib prominence				
Lumbar prominence				
Side				
Kyphosis—more than normal roundness	Yes	No	Yes	No

Negative _____ Refer for second screening _____

Screener's name (print) _____

Check one: School nurse Teacher Volunteer

Clinic assistant Other: _____

Screener notes:

Secondary screening date: ____/____/____

Negative _____ Referred _____

Screener's name (print) _____

Check one: School nurse Health professional

Other: _____

Screener notes:

Date: _____

To the parent/guardian of: _____

Dear parent/guardian,

On _____, _____ conducted the annual state-mandated scoliosis screening for middle school students. A curve of the spine can appear during the years of rapid growth between ages 10 and 15. Findings of the screening indicate your child needs further examination. We recommend that you follow up with your child's primary care physician or provider for an evaluation. If your child does not have a doctor, you may contact the Children's Healthcare of Atlanta Scoliosis Screening Program at **404-785-7553**.

Children's offers a follow-up scoliosis screening that may include X-rays read by a pediatric radiologist. These screenings are offered at Children's locations throughout metro Atlanta. You may schedule an appointment or get additional information by visiting choa.org/scoliosis or calling **404-785-7553**.

Remember to take this letter with you to your child's provider or the provider at a Children's during your child's follow-up screening visit.

Complete the bottom portion of this form and return it to the school's clinic within 15 business days so that we can confirm your receipt of this notice, and note your plans for follow-up. **This information is not mandatory or required.**

Thank you for your cooperation.

(Signature of school nurse/public health nurse)

Date: _____

Return this section to your child's school clinic.

_____ I have received notification for recommendation for further examination of the positive findings of my child's scoliosis screening.

_____ I will contact my child's primary care physician or provider, or the Children's Healthcare of Atlanta's Scoliosis Screening Program to schedule an appointment.

_____ I have noted your correspondence but do not wish to provide any further information.

Student: _____ Grade: _____

Parent/guardian signature: _____ Date: _____

Fecha: _____

A los padres/tutor de _____

Estimado Padre / Tutor,

El _____, _____ llevó a cabo la evaluación anual de escoliosis ordenado por el estado para estudiantes de la escuela intermedia. Durante el período de crecimiento rápido, es decir entre los 10 y 15 años, puede aparecer una curvatura de la columna vertebral. Los resultados de la evaluación indican que su hijo necesita un examen más exhaustivo. Le recomendamos un seguimiento con el médico /proveedor de atención primaria de su hijo para una evaluación. Si su hijo no tiene un médico, puede comunicarse con el Programa de Detección de Escoliosis de Children's Healthcare of Atlanta al **404-785-7553**.

Children's Healthcare of Atlanta ofrece evaluaciones de seguimiento para la detección de la escoliosis que podrían incluir radiografías que son leídas por un radiólogo pediátrico. Estas evaluaciones se ofrecen en todas las ubicaciones de Children's of Healthcare of Atlanta en el área metropolitana de Atlanta. Puede programar una cita u obtener más información visitando **choa.org/scoliosis** o llamando al **404-785-7553**.

Usted debe llevar esta carta a la cita de seguimiento con el proveedor de su hijo o con el proveedor de Children's Healthcare de Atlanta.

Complete la parte inferior de este formulario y devuélvala a la clínica de la escuela dentro de 15 días hábiles, para que podamos confirmar su recibo de este aviso, y anote sus planes para el seguimiento. **Esta información no es obligatoria ni requerida.**

Agradecemos su cooperación

(Firma de la enfermera escolar/enfermera de salud pública)

Fecha: _____

Devolver esta parte a la clínica de la escuela de su hijo.

_____ He recibido la notificación que recomienda un examen más exhaustivo en vista de los hallazgos positivos de la evaluación de escoliosis de mi hijo.

_____ Me comunicaré con el proveedor primario de mi hijo o con el Programa de Detección de Escoliosis de Children's Healthcare of Atlanta's para programar una cita.

_____ He tomado nota de su correspondencia pero no deseo proporcionar más información.

Estudiante: _____ Grado: _____

Firma de uno de los padres/tutor: _____ Fecha: _____

Screening for adolescent idiopathic scoliosis



Children'sSM
Healthcare of Atlanta

Effective screening provides early intervention for an overlooked condition

Scoliosis screening is aimed at identifying suspected cases of scoliosis that will be referred for diagnostic evaluation. The benefits provided by effective clinical scoliosis screening programs are significant, including the detection and referral of patients with adolescent idiopathic scoliosis (AIS) at an earlier stage of the clinical course¹ in addition to the potential prevention of deformity progression by brace treatment and the earlier recognition of severe deformities requiring operative correction.²

Who is affected?

Scoliosis is a lateral deviation from the vertical line (sagittal plane) measured as greater than 10 degrees by X-ray. Vertebral rotation is an additional component.

Evidence supports scoliosis as being hereditary, and current studies indicate that AIS is a complex genetic disorder. The pathogenesis of scoliosis is not fully understood.

Scoliosis affects males and females equally. Females, however, are five times more likely to have a progressive scoliotic curve, requiring treatment.

Because scoliosis has few physical symptoms, a patient complaining of back pain may be symptomatic of another condition.

What are the risks?

The risk of further progression is low for curves measuring less than 30 degrees at the time the patient reaches skeletal maturity. Curves of greater magnitude have a higher risk of progression after maturity, requiring continued observation through the adult years. Some studies report an average of 1 degree of curve progression a year.

When should a child be screened?

Routine screening for scoliosis is important because it decreases the relative risk of curve progression into a surgical range by a factor of eight. The most specific test for scoliosis is the Adams Forward Bend Test.

The at-risk population is between the ages of 10 and 15. At minimum, females should be screened twice, at ages 10 and 12, and males should be screened once, at age 13 or 14².

Georgia General Assembly Code requires screening of public school children for scoliosis³.

What are the treatments?

Observation

Minor curves less than 15 degrees with minimal or moderate risk for progressive deformity need to be observed with periodic clinical physical examination. Observation continues until the risk for progression decreases, usually when the patient reaches skeletal maturity.

Orthotic intervention

Curves between 25 to 45 degrees with moderate or high risk for progression may be managed with a scoliosis brace to limit the risk of further progression until the patient reaches skeletal maturity. The National Institutes of Health (NIH) funded a study published in 2013 that affirmed the efficacy of bracing and the need for early detection of scoliosis. The study conclusively demonstrated that bracing in appropriately indicated patients will result in less surgery.

Surgery

Major curves greater than 45 degrees, or moderate curves with high risk for progression, may require a surgical intervention.

What are the consequences of untreated progressive scoliosis?

- Significant deformity at the spine, which may lead to perceived disability as an adult, such as difficulty completing physical activities (more common in females)
- Development of osteoarthritis of the spine
- Development of chronic back pain, especially in lumbar curves of more than 50 degrees
- Risk during adulthood of additional progression for curves of more than 50 degrees at skeletal maturity
- Potential for decreased vital lung capacity and pulmonary function due to restricted chest diameter in thoracic curves of more than 100 degrees
- Shortness of breath and decreased pulmonary function in thoracic curves of more than 80 degrees
- Increased risk of death from pulmonary and cardiac failure in thoracic curves of more than 100 degrees
- Potential for significant psychological burden on self-image from deformity due to societal emphasis on appearance and health

The Children's difference

Our Scoliosis Screening Program at Children's Healthcare of Atlanta partners with physicians, county health departments and school nurses to detect early signs of scoliosis in the at-risk population.

Scoliosis clinics

- We offer registered nurse-facilitated scoliosis clinics at several metro Atlanta locations with X-ray evaluation for children referred from both physicians and school screenings.
- X-ray results and a treatment recommendation are sent to the families and their primary care physicians.

Referral process

To refer a patient to the scoliosis clinic, have parents call **404-785-7553**.

Additional services and resources

Services

We facilitate access to area pediatric orthopaedic surgeons and additional orthopaedic resources.

Educational opportunities

Our program's registered nurse coordinator provides in-service presentations at physicians' offices in metro Atlanta. Visit choa.org/scoliservice to schedule.

Annual scoliosis screening conference

- Speakers include pediatric orthopaedic surgeons, the program's registered nurse and board-certified orthotists.
- We offer presentations to healthcare professionals, county health department personnel and school nurses about best practices for scoliosis screening.

Resources

- Physician quick reference guide: "Five Steps of Scoliosis Screening"
- Instructional materials for healthcare professionals and volunteers involved in school scoliosis screenings
- Educational materials for patients and families in English and Spanish
- Direct line to the Scoliosis Screening Program's registered nurse at **404-785-6753** to answer questions about scoliosis

Websites

- Scoliosis Research Society: srs.org
- National Scoliosis Foundation: scoliosis.org
- AAOS, SRS, POSNA, AAP position statement on screening for idiopathic scoliosis in adolescents: srs.org/about-srs/quality-and-safety/position-statements/screening-for-the-early-detection-for-idiopathic-scoliosis-in-adolescents



Visit choa.org/scoliosis for more information about scoliosis and our Scoliosis Screening Program.

¹ American Academy of Orthopaedic Surgeons (AAOS), Scoliosis Research Society (SRS), Pediatric Orthopaedic Society of North America (POSNA) and the American Academy of Pediatrics (AAP)

² Hresko M.T., Talwalkar V.R., and Schwend R.M. (Sept. 2, 2015). Screening for the Early Detection of Idiopathic Scoliosis in Adolescents: SRS/POSNA/AAOS /AAP Position Statement. Retrieved from srs.org/about-srs/quality-and-safety/position-statements/screening-for-the-early-detection-for-idiopathic-scoliosis-in-adolescents.

³ Authority O.C.G.A. 20-2-772

Backpacks can be a safe way to carry heavy loads



If children and teens wear them the right way

When backpacks are used correctly, your child should be able to carry his books and supplies without causing problems to his neck, shoulders and back.

What kind of backpack should my child use?

Choose a backpack made of light material, such as canvas or nylon. Be sure it is the right size for your child.

Look for:

- Wide, padded shoulder straps
- Padded back
- Waist strap
- Multiple compartments

Reflective strips on the bag are recommended. They make the child easier to see before sunrise and at night.

How do I pack a backpack?

Always pack the backpack so that most of its weight rests low on your child's back near the waist. Pack the heaviest books closest to the body and distribute other items equally on the right and left sides.

Your child should:

- Bend his knees to pick up a backpack.
- Clean his backpack weekly to take out things he does not need.
- Put things in his locker so his backpack is not heavy.
- Take only what is needed to school.

How much should a backpack weigh?

Backpacks should not weigh more than 10 to 15 percent of your child's body weight. This means a child who weighs 100 pounds should have a backpack that weighs no more than 10 to 15 pounds.

- If your child needs to lean forward to support the weight of his backpack, it is too heavy.
- Use backpacks with wheels and handles if your child needs to carry more than 15 percent of his body weight.

How should my child wear the backpack?

Your child should wear it so that it puts weight on the strongest muscles in the body: back and stomach.

This means:

- Your child should wear both straps over his shoulders.
 - Adjust the shoulder straps so the backpack rests in the middle of his back.
 - The backpack should fit close to his body.
- Secure the waist strap.
 - This helps keep the backpack close to his body.
- Pack items in compartments.
 - This helps distribute heavy loads evenly.
- Make sure the bottom of the backpack rests in the curve of the lower back.
- Check the height of the backpack.
 - It should extend from the waistline to about 2 inches below the shoulders.
- The backpack should never sit more than 4 inches below the waistline.

What else can I do to help my child?

Talk to your child and his teachers to make sure there are no problems. For example, if your child is having back problems and has a heavy book, ask if he can have a second book to keep at home.

Ask your child to tell you if he has any of the following in his back, shoulder or neck:

- Pain
- Numbness (lack of feeling)
- Tingling (itchy or stinging feeling)

This is general information and not specific medical advice. Always check with a doctor or healthcare provider if you have questions or concerns about the health of a child.

Las mochilas pueden ser seguras para transportar cargas pesadas



Si los niños y adolescentes las usan correctamente

Cuando las mochilas se usan correctamente, su niño podría llevar sus libros y materiales sin causarse problemas en el cuello, hombros y columna.

¿Qué tipo de mochila debe usar mi niño?

Escoja una mochila que sea de material liviano, como lona o nylon, y asegúrese de que sea del tamaño correcto para el niño.

Fíjese que tenga:

- Correas para los hombros, que sean anchas y acolchadas
- Respaldo acolchado
- Correa para la cintura
- Compartimentos múltiples

Se recomienda que la mochila tenga cintas reflectantes, ya que facilitan que el niño pueda verse antes del amanecer y durante la noche.

¿Cómo empaco la mochila?

Empáquela siempre de manera que la mayor parte del peso descansa en la parte baja de la espalda de su niño, cerca de la cintura. Empaque los libros más pesados cerca del cuerpo y distribuya otros artículos de manera uniforme tanto en el lado derecho como en el izquierdo.

Su niño debe:

- Doblar las rodillas para levantar la mochila.
- Limpiar la mochila semanalmente para sacar las cosas que no necesita.
- Dejar cosas en el *locker* para que la mochila no sea tan pesada.
- Llevar a la escuela solamente lo necesario.

¿Cuánto debe pesar la mochila?

Las mochilas no deben pesar más del 10 al 15 por ciento del peso corporal de su niño. Esto significa que un niño que pesa 100 libras no debe cargar una mochila que pese más de 10 a 15 libras.

- Si su niño se debe inclinar hacia adelante para sostener el peso de su mochila, entonces está muy pesada.
- Si su niño debe cargar más del 15 por ciento de su peso corporal, use mochilas con ruedas y agarraderas.

¿Cómo debe mi niño cargar la mochila?

Su niño debe llevarla de forma tal que ponga el peso en los músculos más fuertes del cuerpo: la espalda y el estómago.

Esto significa que:

- Su niño debe ponerse ambas correas sobre los hombros.
 - Ajustar las correas de los hombros de manera que la mochila descansa en el centro de la espalda.
 - La mochila debe quedar pegada al cuerpo.
- Debe abrochar la correa para la cintura.
 - Esto ayuda a mantener la mochila cerca de su cuerpo.
- Empaque los objetos en compartimentos.
 - Esto ayuda a distribuir uniformemente las cargas pesadas.
- Asegúrese de que el fondo de la mochila descansa en la curva de la parte baja de la espalda.
- Verifique la altura de la mochila.
 - Esta debe ir desde la cintura hasta 2 pulgadas por debajo de los hombros.
- La mochila nunca debe quedar más de 4 pulgadas por debajo de la cintura.

¿Qué más puedo hacer para ayudar a mi niño?

Hable con su niño y los maestros para estar seguro de que no hay problemas. Por ejemplo, si su niño sufre de problemas de espalda y tiene un libro pesado, pida que le presten otro para tener en casa.

Pida a su niño que le informe si presenta cualquiera de los siguientes en la espalda, hombros o cuello:

- Dolor
- Entumecimiento (falta de sensibilidad)
- Hormigueo (picazón o sensación de ardor)

Esta es información general; no es un consejo médico específico. Si tiene preguntas o inquietudes sobre la salud de un niño, verifique siempre con un médico o un proveedor de salud.

Five-step scoliosis screening process for healthcare professionals

First position:

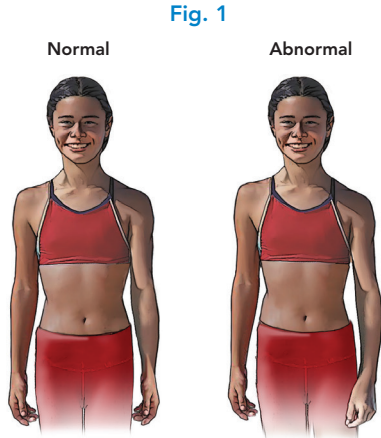
Anterior view, standing position

Instructions to the child:

- Face the screener. Put your feet together with equal weight on both legs.
- Breathe in. Let it out, and relax your shoulders. Let your arms hang naturally at your sides.

Look for (see Fig. 1):

- Shoulder height asymmetry
- Unequal distance between arms and torso
- Hip prominence or asymmetry



Second position: Anterior view, Adams forward bend test

Instructions to the child (see Fig. 2):

- Put your palms together with arms out straight.
- Put your chin on your chest and roll down until your hands touch your feet.

Note: Encourage the child to continue to roll down as far as possible until his back is parallel to the floor. Have the child repeat the Adams forward bend test if he rolls down too quickly or if he rolls down to one side or the other. (The child's hands should be pointing at the big toes.)

Look for (see Fig. 3):

- Upper thoracic asymmetry
- Lower thoracic asymmetry
- Lumbar asymmetry

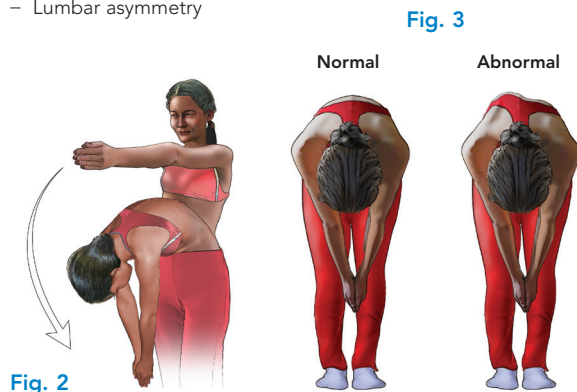


Fig. 2

Third position: Posterior view, standing position

Instructions to the child:

- Turn around (child's back is now to screener).
- Put your feet together with equal weight on both legs.
- Breathe in. Let it out and relax your shoulders. Let your arms hang naturally at your sides.

Look for (see Fig. 4):

- Shoulder height asymmetry
- Scapula prominence or asymmetry
- Unequal distance between arms and torso
- Waist crease asymmetry or no waist crease on one side
- Spine curved to one side

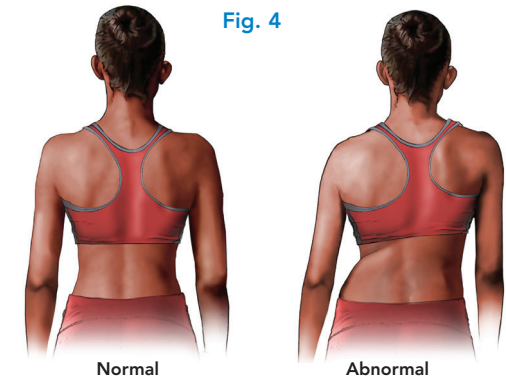


Fig. 4

Fourth position: Posterior view, Adams forward bend test

Instructions to the child:

- Put your palms together with arms out straight.
- Put your chin on your chest and roll down until your hands touch your feet.

Note: Encourage the child to continue to roll down as far as possible until his back is parallel to the floor. Have the child repeat the Adams forward bend test if he rolls down too quickly or if he rolls down to one side or the other. (The child's hands should be pointing at the big toes.)

Look for (see Fig. 5):

- Upper thoracic asymmetry
- Lower thoracic asymmetry
- Lumbar asymmetry

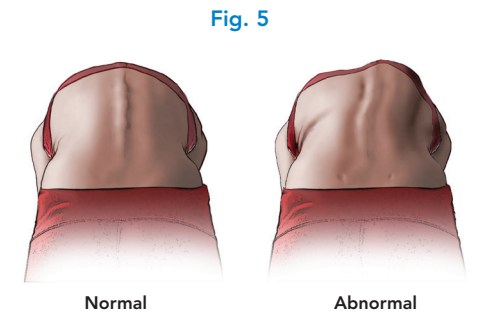


Fig. 5

Fifth position: Sagittal view, Adams forward bend test

Instructions to the child:

- Turn to the side. Put your feet together with equal weight on both legs.
- Put your palms together with arms out straight.
- Put your chin on your chest and roll down until your hands touch your feet.

Look for (see Fig. 6):

- Sharp angle/abnormal contour in low thoracic area (kyphosis)

Note: Encourage the child to continue to roll down as far as possible until his back is parallel to the floor. Have the child repeat the Adams forward bend test if he rolls down too quickly or if he rolls down to one side or the other. (The child's hands should be pointing at the big toes.)

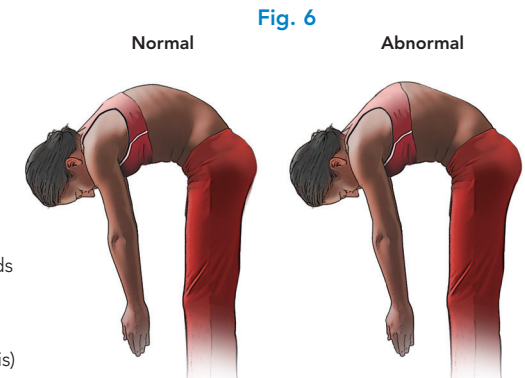


Fig. 6



Visit choa.org/scoliosis or call 404-785-7553 for more information.

Five-step scoliosis screening process for volunteers

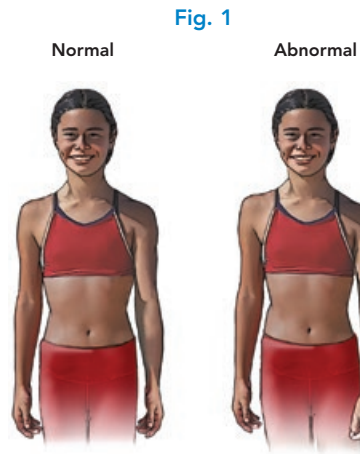
First position: Front, standing position

Instructions to the child:

- Face the screener. Put your feet together with equal weight on both legs.
- Breathe in. Let it out, and relax your shoulders. Let your arms hang naturally at their sides.

Look for (see Fig. 1):

- Uneven shoulders (Is one shoulder higher?)
- Arm hanging out farther from body on one side
- Hip that appears higher on one side



Second position: Front, bending forward (Adams forward bend test)

Instructions to the child (see Fig. 2):

- Put your palms together with arms out straight.
- Put your chin on your chest and roll down until your hands touch your feet.

Note: Encourage the child to continue to roll down as far as possible until his back is parallel to the floor. Have the child repeat the Adams forward bend test if he rolls down too quickly or if he rolls down to one side or the other. (The child's hands should be pointing at the big toes.)

Look for (See Fig. 3):

- Upper rib prominence on one side
- Lower rib prominence on one side
- Lower back (lumbar) prominence on one side

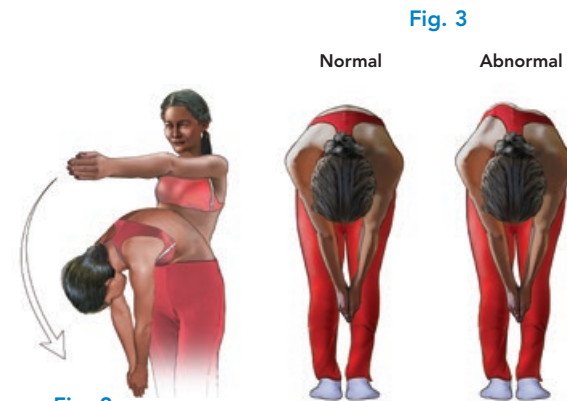


Fig. 2

Third position: Back, standing position

Instructions to the child:

- Turn around, (child's back is now to screener), put your feet together with equal weight on both legs.
- Breathe in. Let it out and relax your shoulders. Let your arms hang naturally at their sides.

Look for (See Fig. 4):

- Uneven shoulders (Is one shoulder higher?)
- Shoulder blade (scapula) more prominent than other or one higher
- Arm hanging out farther from body on one side
- Waist fold deeper on one side

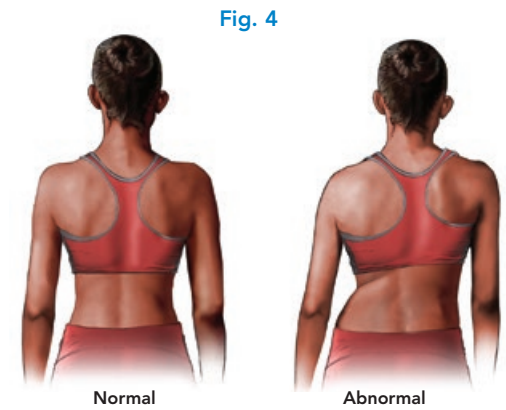


Fig. 4

Fourth position: Back, bending away (Adams forward bend test)

Instructions to the child:

- Put your palms together with arms out straight.
- Put your chin on your chest and roll down until your hands touch your feet.

Note: Encourage the child to continue to roll down as far as possible until his back is parallel to the floor. Have the child repeat the Adams forward bend test if he rolls down too quickly or if he rolls down to one side or the other. (The child's hands should be pointing at the big toes.)

Look for (See Fig. 5):

- Upper rib prominence on one side
- Lower rib prominence on one side
- Lower back (lumbar) prominence on one side

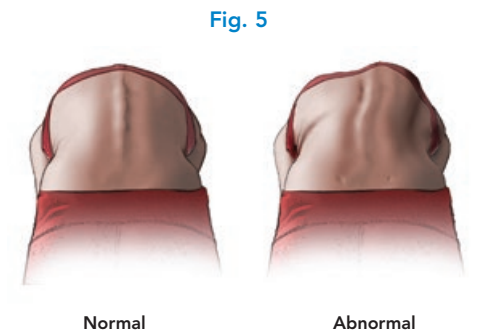


Fig. 5

Fifth position: Side, in a bending position (Adams forward bend test)

Instruction to the child:

- Turn to the side. Put your feet together with equal weight on both legs.
- Put your palms together with arms out straight.
- Put your chin on your chest and roll down until your hands touch your feet.

Look for (See Fig. 6):

- Normal "c" shaped curve or more than normal roundness (kyphosis)

Note: Encourage the child to continue to roll down as far as possible until his back is parallel to the floor. Have the child repeat the Adams forward bend test if he rolls down too quickly or if he rolls down to one side or the other. (The child's hands should be pointing at the big toes.)

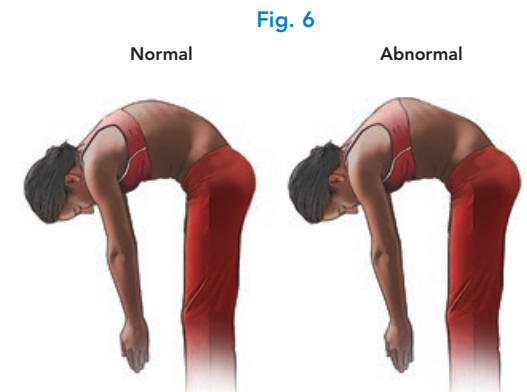


Fig. 6