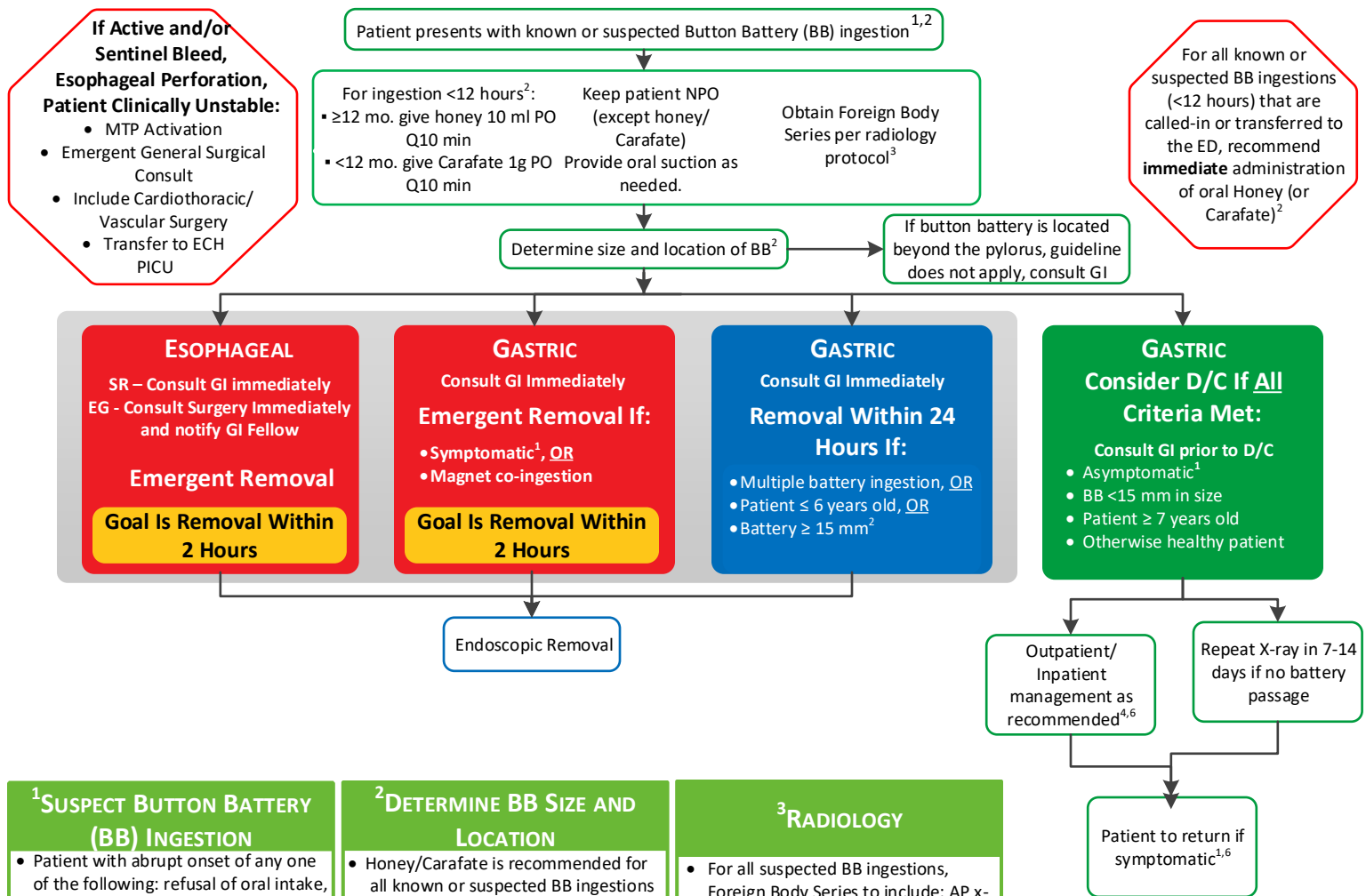




(see [Button Battery Ingestion Clinical Practice Guideline](#) for complete recommendations)



¹SUSPECT BUTTON BATTERY (BB) INGESTION

- Patient with abrupt onset of any one of the following: refusal of oral intake, difficulty swallowing, chest pain, drooling, airway obstruction, or wheezing or stridor without typical prodromal symptoms of viral illness.
- Presumed “coin” shape ingestion.
- **For patients presenting to an Urgent Care center with BB ingestion, immediately begin Honey/Carafate and contact Transfer Center for Emergent transfer to ECH or SR.**
- Batteries located in the esophagus may be asymptomatic initially. **Do not wait for symptoms to appear.** Serious burns can occur within 2 hours.
- Do not induce vomiting or give cathartics
- Consult the National Battery Hotline at 800-498-8666 (or 202-625-3333) as needed for assistance in battery identification & patient management

Symptoms of BB ingestion include: Occult or visible bleeding, persistent or severe abdominal pain, vomiting, signs of acute abdomen and/or fever, and/or profoundly decreased appetite (unless symptoms unrelated to battery ingestion)

²DETERMINE BB SIZE AND LOCATION

- Honey/Carafate is recommended for all known or suspected BB ingestions **within the past 12 hours** (increased risk of esophageal perforation if >12 hours)
- Begin honey/Carafate once BB ingestion suspected. If X-ray shows **esophageal location**, continue until patient reaches the OR. Discontinue if battery located in the stomach.
 - If ≥12 mo. give honey 10 ml PO Q10 min, max 6 Doses*
 - If <12 mo. give Carafate 1g PO Q10 min, max 3 doses*
- *May exceed max doses per MD order
- 1 honey packet (9.2 ml) is acceptable substitute for 10 ml dose
- Chemical content & diameter of the BB can be determined from imprinted code found on the battery case
- Assume hearing aid batteries are <12mm
- Cylindrical batteries pose a lower threat for caustic damage after ingestion than BB, but due to their size may become trapped in the stomach. Any cylindrical battery ingestions warrant prompt x-ray evaluation & urgent endoscopic removal if located in the esophagus.
- Removal of gastric BB <15mm at the discretion of consulting provider

³RADIOLOGY

- For all suspected BB ingestions, Foreign Body Series to include: AP x-ray nose to rectum & lateral x-ray neck. If circular metallic foreign body identified in chest, obtain lateral x-ray of chest to evaluate position of negative battery pole.

⁶OUTPATIENT MANAGEMENT

- Button batteries that have cleared the stomach usually pass the GI tract within 1 week without complications.
- Anticipatory guidance to include close monitoring for bloody emesis, melena, cough, and fever, and/or abdominal pain
- Patients with symptoms of abdominal pain, hematochezia, or fever should seek immediate medical attention for emergent X-rays.
- **Prompt surgical removal is indicated for symptomatic patients with radiographic confirmation of a retained intestinal Button Battery**

ESOPHAGEAL EMERGENT REMOVAL: Scottish Rite: The GI group will retain the primary responsibility for removal of the battery and making immediate post removal decisions (including involvement of Surgery and transfer to ECH PICU).

EG: The surgeons will be called by the ED and will be primarily responsible for the removal. The ED will also notify the GI fellow on call as well and ideally, the procedure will be a joint procedure between Surgery and GI.